

# Cerebral Vascular Anatomy

# 2

Hyoung Soo Byoun and Gyojun Hwang

## Abstract

The brain is about 2% of the body's weight, weighing between 1250 and 1450 g. The heart sends 15% of all blood to the brain, and 20% of total oxygen is consumed by the brain. Strokes occur due to problems with blood supply to the brain, and these can include hemorrhage, infarction, and transient ischemic attack. The emergent and proper management for strokes should be performed immediately and can prevent or minimize the otherwise devastating consequences. A fundamental concept of territories of the brain supplied by cerebral vessels and the functions of these territories is essential for effective therapeutic approach to stroke. At this point, defining and understanding cerebrovascular anatomy is the cornerstone to safe and successful treatment of stroke.

This chapter addresses the basic anatomical structures, courses, relationships, and functions of the cerebral vessels.

H. S. Byoun  
Department of Neurosurgery, Chungnam National University Hospital, Daejeon, Republic of Korea

G. Hwang (✉)  
Department of Neurosurgery, Bundang Jesaeng General Hospital, Seongnam, Republic of Korea

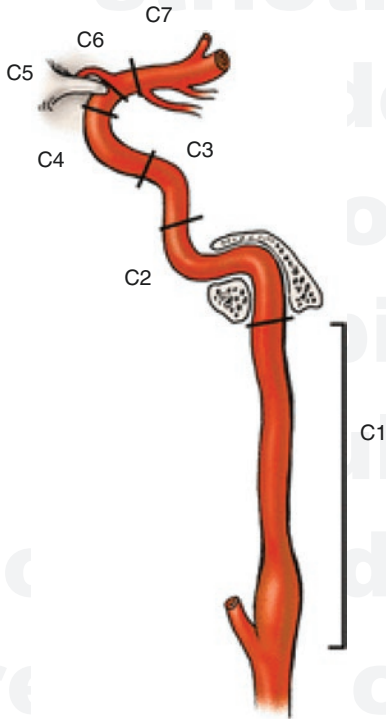
## 2.1 Introduction

The cerebral blood flow is supplied by the internal carotid arteries (ICAs) and vertebral arteries (VAs) [1]. The ICAs take charge of the anterior circulation and the VAs take charge of the posterior circulation, sending 80 and 20% of the cerebral blood flow. The circle of Willis is an anastomotic system of arteries located at the base of the brain connecting anteroposterior and bilateral flows. The right innominate artery, left common carotid artery (CCA), and subclavian artery originate from the aortic arch. The right innominate artery is then divided into right CCA and right subclavian artery. The right VA originates from right subclavian artery and the left VA from the left subclavian artery. The CCA bifurcates to the ICA and the external carotid artery (ECA) at the level of the C4 vertebral body. Then, the anterior cerebral artery (ACA) and middle cerebral artery (MCA) are separated from the ICA. After branching of the posterior inferior cerebellar artery (PICA) from both VAs, the basilar artery (BA) is formed by the union of two VAs. As it ascends superiorly, the BA ramifies the anterior inferior cerebellar artery (AICA) and superior cerebellar artery (SCA), and is divided into two posterior cerebral arteries (PCAs).

## 2.2 Internal Carotid Artery

The ICA separates from the CCA at the level of fourth cervical vertebrae, and passes through the carotid canal into the cranium [2]. The diameters of the CCA, carotid bulb, and proximal ICA are approximately 7.0 mm, 7.5 mm, and 4.5 mm, respectively [3]. The ICA penetrates the petrous bones, the cavernous sinus, and the dura, and finally separates into the ACA and MCA.

The ICA segment is divided into seven segments: cervical, petrous, lacerum, cavernous, clinoid, ophthalmic, and communicating segments from the bottom (Fig. 2.1).



A. Bouthillier *et al.*, 1996

**Fig. 2.1** The classification scheme of the internal carotid artery. C1, cervical; C2, petrous; C3, lacerum; C4, cavernous; C5, clinoid; C6, ophthalmic; and C7, communicating segment. Adapted with permission from *Essential Neurovascular Anatomy*, Copyright Springer Nature [4]

### 2.2.1 Segments of the ICA

#### 2.2.1.1 Cervical Segment

The cervical segment of the ICA is the section from the CCA bifurcation to the carotid canal of the temporal bone. The ICA is initially located at the posterolateral portion of the ECA and then courses medially to the ECA as it ascends toward the carotid canal. The ICA lies anteromedial to the internal jugular vein. The glossopharyngeal nerve, vagus nerve, accessory nerve, and hypoglossal nerve course between the ICA and the internal jugular vein [5]. There is no important branch arising from this segment.

#### 2.2.1.2 Petrous Segment

The petrous segment of the ICA enters the skull base through the carotid canal and courses in the petrous temporal bone. This segment subdivides into the short vertical segment, genu, and long horizontal segment. The sympathetic chain and venous plexus surround the petrous segment [6]. The caroticotympanic artery and vidian artery arise from this segment.

#### 2.2.1.3 Lacerum Segment

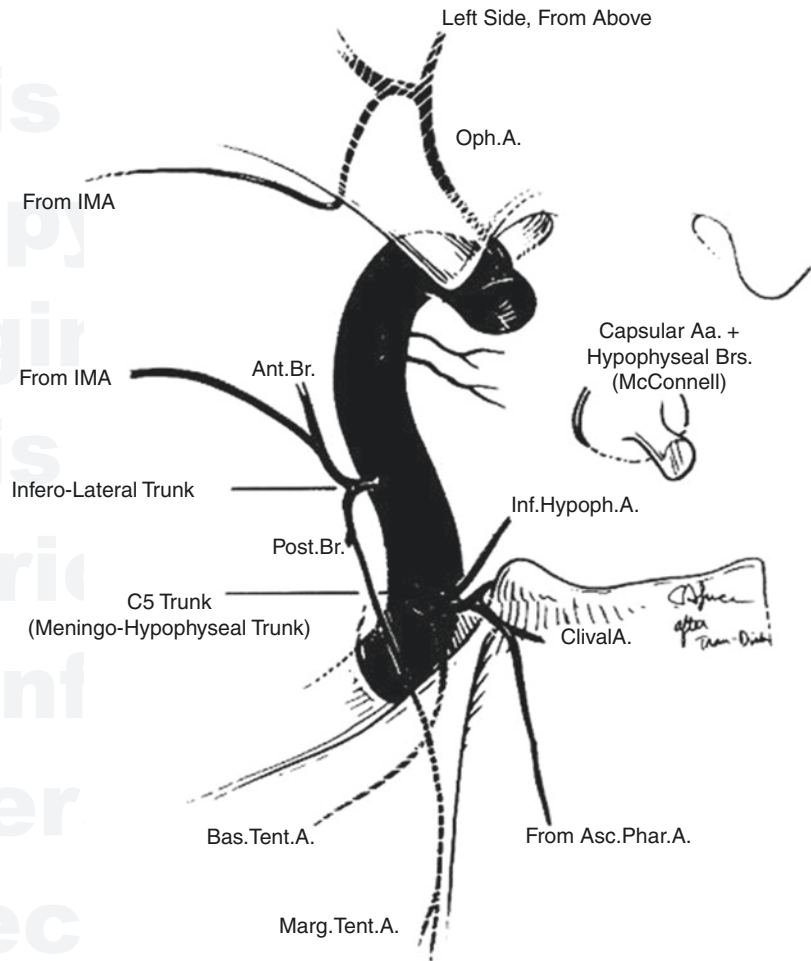
The lacerum segment of the ICA is a section from the end of the petrous segment to the petrolingual ligament (Fig. 2.1).

#### 2.2.1.4 Cavernous Segment

The cavernous segment of the ICA begins from the petrolingual ligament and enters the cavernous sinus. It consists of the posterior genu, horizontal segment, and anterior genu. The meningohypophyseal trunk, inferolateral trunk, and capsular arteries of McConnell arise from the cavernous segment of the ICA (Figs. 2.1 and 2.2).

The meningohypophyseal trunk arises from the posterior genu of the cavernous segment of the ICA. It ramifies three branches including the tentorial arteries, inferior hypophyseal artery, and lateral clival artery. The tentorial arteries course medially and superiorly along the margin of the tentorial incisura or run laterally and inferiorly

**Fig. 2.2** The branches of cavernous internal carotid artery segments. Adapted with permission from Neurology, Copyright Wolters Kluwer Health [7]



into the tentorium. Near the petrous ridge and sigmoid sinus, they connect with the middle meningeal artery and dural arteries of the posterior fossa. The inferior hypophyseal artery which anastomoses with the superior hypophyseal artery and its contralateral flow supplies the pituitary gland. The clival artery supplies dura covering the clivus and has a connection with the ascending pharyngeal artery of the ECA.

The inferolateral trunk that arises from the lateral aspect of the horizontal ICA segment supplies the oculomotor nerve, trochlear nerve, gasserian ganglion of the trigeminal nerve, abducens nerve, dura mater of the cavernous sinus, and tentorium. It connects with several branches from the ECA including branches of the internal maxillary artery and the ascending pharyngeal artery.

The capsular arteries of McConnell arise from the medial aspect of the cavernous segment of the ICA and supplies the pituitary gland irregularly. They are too small to be seen during angiography in the normal state. Medially directed aneurysms of cavernous segments of the ICA can present in these arteries. They can penetrate the diaphragm sellae and occupy the sellae to cause subarachnoid hemorrhage (if ruptured) and hypopituitarism. These branches of the cavernous segment serve as important collaterals in the ICA occlusion.

### 2.2.1.5 Clinoidal Segment

The clinoidal segment of the ICA is the section from proximal dural ring to distal dural ring. It is the shortest section of the ICA. There is no branch arising from the clinoidal segment of the ICA.

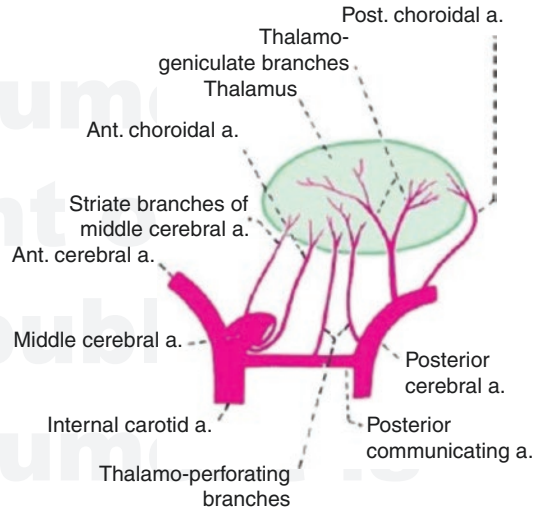
### 2.2.1.6 Ophthalmic Segment

The ophthalmic segment of the ICA is the section from the distal dural ring to the origin of the posterior communicating artery. The ophthalmic artery and superior hypophyseal artery arise from this section (Fig. 2.1). The ophthalmic artery has important branches including the central retinal artery, the anterior and posterior ethmoidal arteries, lacrimal branch, recurrent meningeal branch, and branches supplying muscles and orbital content. They may receive collateral flows from the ECA when the ICA is occluded [8]. A connection between the facial or superficial temporal artery and the lacrimal branch can serve as an important collateral route. The recurrent meningeal branch can collateralize with the middle meningeal artery or the inferior lateral trunk of the cavernous segment of ICA.

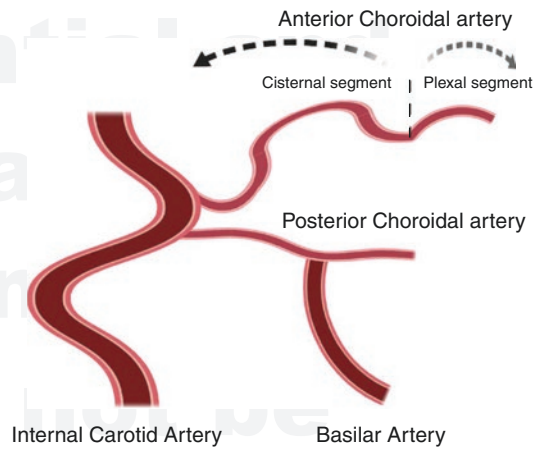
### 2.2.1.7 Communicating Segment

The communicating segment of the ICA is a section from the origin of the posterior communicating artery (PCoM) to the bifurcation of the ICA. The PCoM and anterior choroidal arteries (AChA) arise from this section (Fig. 2.1).

The anterior thalamoperforator arteries (the most prominent branch of the anterior thalamoperforators is called premamillary artery or tuberothalamic artery), seven to ten in number, come from the superolateral aspect of the middle third of the PCoM (Fig. 2.3). They supply the anterior portion of the thalamus, mammillothalamic tract, ventral amygdalofugal pathway, internal medullary lamina, posterior aspect of the optic chiasm, the proximal portion of the optic radiations, the posterior hypothalamus, and cerebral peduncle [9]. Twenty percent of people have fetal-type PCoM which is a common variant. In individuals with fetal type PCoM, the P1 segment of the PCA is absent or hypoplastic [10, 11]. The AChA arises from the posterior wall of the ICA between the origin of the PCoM and the ICA bifurcation (Fig. 2.4). It is divided into two main segments: cisternal segment and intraventricular segment. The cisternal segment courses posterior medially below the optic tract and superomedially below the temporal lobe uncus then it turns laterally. After it curves around the cerebral peduncle in



**Fig. 2.3** Perforating branches of the thalamus. Adapted with permission from brainkart.com



**Fig. 2.4** The schematic illustration of angiographic feature of the anterior choroidal artery. ICA internal carotid artery, BA basilar artery, and PCoA posterior communicating artery

the crural cistern, it continues toward the lateral geniculate body. It turns sharply toward the choroidal fissure near the lateral geniculate body, and then, it enters the temporal horn through the choroidal fissure and the intraventricular segment begins. The sharp angle of the AChA at the choroidal fissure is known as the "plexal point." The intraventricular segment continues along the choroidal plexus and curves around the pulvinar of the thalamus anteriorly. The AChA supplies the



uncus, piriform cortex, tail of the caudate nucleus, hippocampus, amygdala, thalamus, lateral geniculate body, optic tract, genu and posterior limb of internal capsule, cerebral peduncle, choroid plexus, and subthalamic nucleus. Occlusion of the AChA causes clinical symptoms which include variable degrees of hemianesthesia, contralateral hemiplegia, and hemianopsia with memory loss and somnolence [12].

### 2.2.2 Anatomic Variants of the ICA

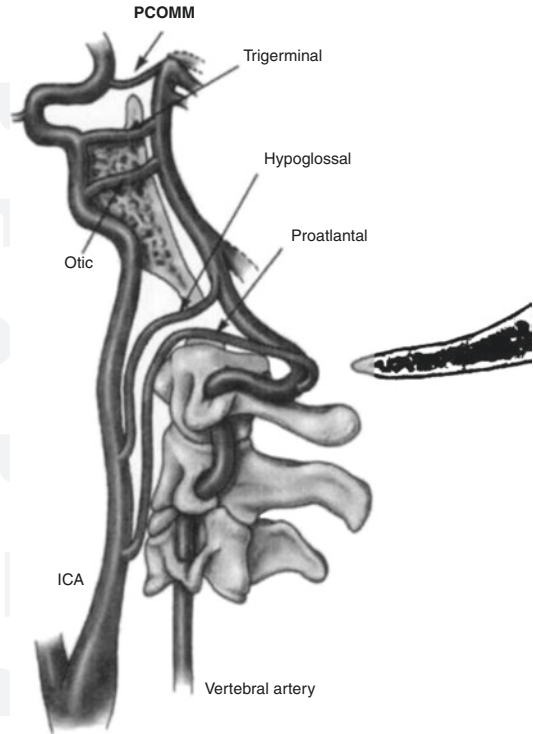
Agenesis of the ICA has been reported rarely. Unilateral agenesis of the ICA is more common than bilateral agenesis. Due to the development of the collateral circulations or alternative routes, clinical symptoms may not occur. This agenesis can be confirmed by absence of the carotid canal.

The aberrant ICA is thought to be associated with atresia or regression of the cervical portion of the ICA. It usually occurs bilaterally and may be misdiagnosed as a middle ear mass on axial images. Pseudoaneurysm and severe bleeding may occur due to biopsy of the misdiagnosed lesion.

### 2.2.3 Carotid-Basilar Anastomoses

Transient segmental connections between the primitive carotid and hindbrain circulations including the trigeminal, otic, hypoglossal, and proatlantal intersegmental arteries, present during development of fetal craniocerebral circulation (Fig. 2.5). These vessels course parallel with the cranial nerves and are named according to these nerves except for the extracranial proatlantal intersegmental arteries. Normally, these vessels disappear as the PComs develop. However, if these vessels are not obliterated and persist into adulthood, they are termed carotid-basilar anastomoses.

The persistent trigeminal artery is the most common of four carotid-basilar anastomoses. It arises from the posterior genu of the cavernous ICA. It curves laterally and posteriorly around the dorsum sellae, following the trigeminal nerve



**Fig. 2.5** Carotico-basilar anastomoses. Adapted with permission from American Journal of Roentgenology, Copyright American Roentgen Ray Society [13]

(parasellar course) or directly posteriorly to pierce the dorsum sellae to anastomose with the basilar artery (intrasellar course). The persistent trigeminal artery is frequently associated with other vascular abnormalities including aneurysm. The primitive otic artery arises from the petrous segment of the ICA. It emerges from the internal auditory meatus and joins the BA. The persistent otic artery is extremely rare. The persistent hypoglossal artery, the second most common anastomosis, arises from the cervical segment of the ICA at the level of C1 or C2. After that it curves posteromedially to the hypoglossal canal and passes through the hypoglossal canal to join the BA without passing the foramen magnum. In cases of persistent hypoglossal artery, the PCom is absent and the ipsilateral VA is hypoplastic. The proatlantal intersegmental artery arises from ICA (type 1) or ECA (type 2) at the level of C2 or C3, and runs posterolaterally and superiorly outside of the intervertebral foramen. Then, it passes through the foramen magnum and joins the VA.

## 2.3 Anterior Cerebral Artery

The ACA supplies the medial aspects of cerebral hemisphere, lentiform nucleus, and base of the frontal lobe (Fig. 2.6). The ACA is divided into three segments [14, 15]:

- A1: precommunicating segment (horizontal)
- A2: postcommunicating segment (vertical)
- A3: distal segment

The A1 segment extends horizontally from the ICA bifurcation to the origin of the anterior communicating artery (ACoM). Divided from the ICA, it courses medially toward the interhemispheric fissure over the optic nerve or optic chiasm and below the anterior perforated substance.

If the A1 segment is hypoplastic or absent, the opposite A1 supplies both ACA territories through the ACoM. The ACoM complex has variations according to the relative size of the A1 segment and the ACoM. If the diameter of the A1 segment is 1.5 mm or less, it is defined as hypoplastic. The ACoM varies in diameter up to 3.4 mm, in length up to 7 mm. The greater the diameter of the ACoM, the more asymmetry of the A1 segments occurs. Asymmetry of the A1

segments may affect aneurysm formation in the ACoM [16, 17].

The A2 segment is the section from the origin of the ACoM to the junction where the rostrum of corpus callosum and genu of corpus callosum meet. It courses upward within the interhemispheric fissure, anterior to the lamina terminalis and rostrum of corpus callosum.

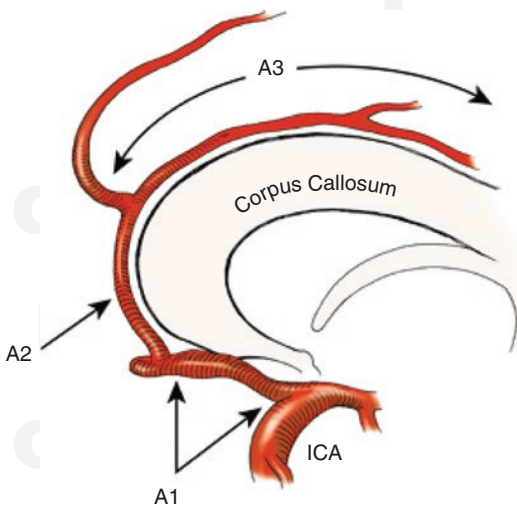
The A3 segment begins at a point where the ACA is divided into the pericallosal artery and callosomarginal artery around the genu of corpus callosum. The callosomarginal artery courses over the cingulate gyrus and within the cingulate sulcus posteriorly. The pericallosal artery runs posteriorly above the corpus callosum with various lengths.

### 2.3.1 Perforating Branches

The medial lenticulostriate artery arises from the A1 segment, runs posterosuperiorly through the anterior perforated substance (Fig. 2.7). It supplies anterior hypothalamus, septum pellucidum, the medial part of the anterior commissure, the pillars of the fornix, and the anterior aspect of the striatum [14, 19].

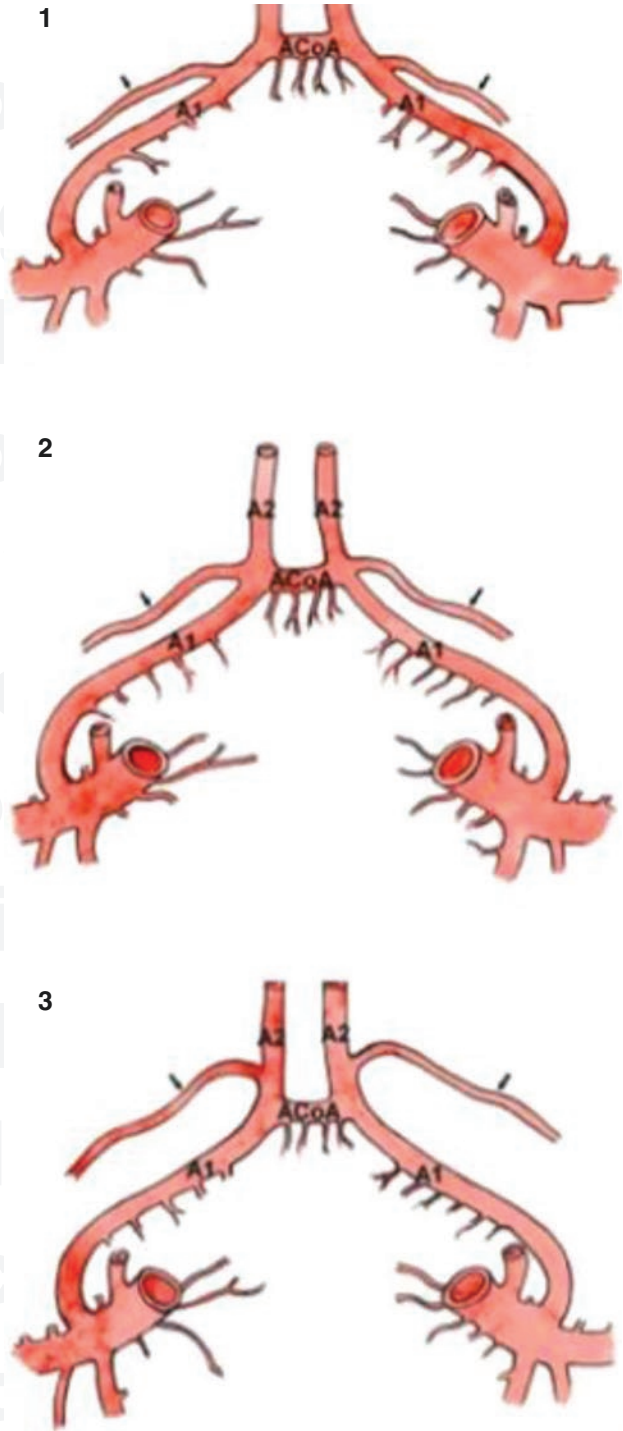
The recurrent artery of Heubners arises from the proximal portion of the A2 segment (34–50%), A1 segment (17–45%), or ACoM (5–20%) (Fig. 2.7). It runs back on the course of its parent vessel. It courses laterally above the A1 and M1 segments and supplies the head of the caudate nucleus, anterior limb of the internal capsule, anterior portion of the hypothalamus, and globus pallidus. Then, it terminates in the lateral aspect of the anterior perforated substance [20].

Inferiorly directed small perforating branches from A1, proximal A2, and ACoM supply the optic chiasm and nerve. Also, perforating branches from the ACoM are directed toward the anterior cingulum, corpus callosum, fornix, and septal region. The anterior basal perforating branches of the ACoM complex supply the hypothalamic region. If these vessels are injured, neurologic and psychiatric syndromes will be generated [14, 21, 22].



**Fig. 2.6** The segments of anterior cerebral artery. Adapted with permission from *Essential Neurovascular Anatomy*, Copyright Springer Nature [4]

**Fig. 2.7** The areas of origin of the recurrent artery of Heubner. Adapted with permission from BioMed Research International [18]

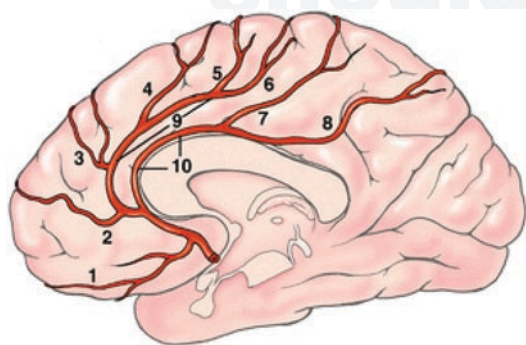


### 2.3.2 Cortical Branches

The cortical branches are named according to the territory perfused (Fig. 2.8). Normally, cortical branches do not arise from the A1 segment. First cortical branches arise from the proximal A2 segment. These vessels supply the orbital surface of the frontal lobe (orbitofrontal artery). Second cortical branches also arise from the proximal A2. The most prominent branch of these is called the frontopolar artery arising below the rostrum or genu of corpus callosum and coursing anteriorly to the frontal pole. The anterior, middle, and posterior internal frontal artery and precentral arteries which are ramified from the callosomarginal artery supply the medial surface of the hemisphere above the corpus callosum of frontal and precuneus as well as the adjacent convexity. The superior and inferior parietal arteries arising from the pericallosal artery represents continuation of the main ACA trunk supplying the medial surface above the corpus callosum of the parietal lobe.

### 2.3.3 Anomalies of the ACA

The ACA in rare cases arises from the region that located a few millimeters above the intradural ICA. In this situation which is called infraoptic origin of the ACA, the ACA courses medially

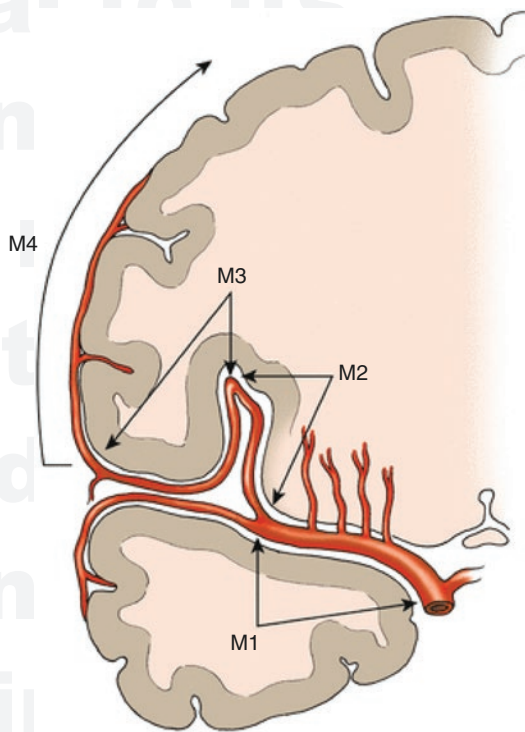


**Fig. 2.8** The distal branches of anterior cerebral artery. (1) Orbitofrontal artery; (2) frontopolar artery; (3) anterior internal frontal artery; (4) middle internal frontal artery; (5) posterior internal frontal artery; (6) paracentral artery; (7) superior parietal artery; (8) inferior parietal artery; (9) callosomarginal artery; and (10) pericallosal artery. Adapted with permission from Essential Neurovascular Anatomy, Copyright Springer Nature [4]

below the optic nerve and then curves superiorly to the AComA. This anomaly is associated with other anomalies including aneurysm, agenesis of hypoplasia of the A1, and carotid agenesis. Accessory ACA arises from the ICA and courses under the optic nerve to supply the medial and basal area of the frontal lobe. Azygous ACA that is a single unpaired ACA is formed due to the embryonic median artery of the corpus callosum remaining. It is associated with an increased risk of aneurysm or other anomalies. Bihemispheric ACA is similar to azygous ACA. However, it has one hypoplastic A2 and the other dominant A2 divides into branches that supply both hemispheres.

### 2.4 Middle Cerebral Artery

After the ACA is separated at the ICA bifurcation, the MCA passes through the sylvian fissure and insula, and supplies a wide area on the surface of the cerebrum (Fig. 2.9). The MCA are divided into four segments [23–25]:



**Fig. 2.9** The middle cerebral artery. Adapted with permission from Essential Neurovascular Anatomy, Copyright Springer Nature [4]



- M1: horizontal segment
- M2: insular segment
- M3: opercular segment
- M4: cortical segment

The M1 segment is the horizontal section from the ICA bifurcation to the limen insulae and courses below the anterior perforated substance. It is divided into prebifurcation and postbifurcation segments at a point where the MCA is divided into superior and inferior divisions. The MCA main trunk can be divided into four patterns such as a single trunk with no main division, a bifurcation, a trifurcation, or multiple trunks. Of these, the bifurcation pattern is the most common (up to 90%). Near the limen insulae, the postbifurcation segment curves upward in a gentle angle, forming “genu.”

The M2 segment extends from the genu to the top of the circular sulcus of the insula. It consists of six to eight major stem arteries. In bifurcation pattern, superior and inferior division of the M2 segments course in posterosuperior and postero-inferior directions at the genu, respectively. The M3 segment begins at the top of the insula and turn laterally within the sylvian fissure (opercular turn). After exiting the sylvian fissure, the M4 segments become visible on the lateral convexity of the hemisphere and they spread to the outer part of frontal, parietal, temporal occipital lobe, and widely supply the cerebral cortex.

#### 2.4.1 Perforating Branches

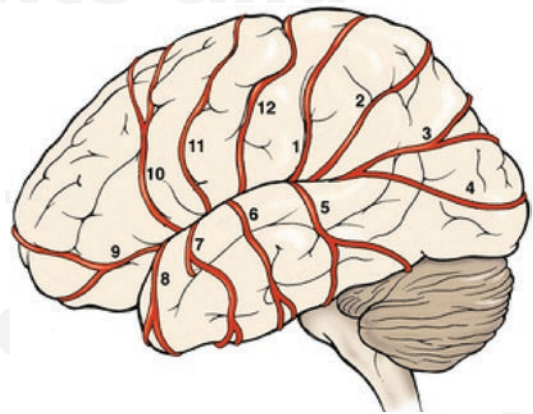
The lateral lenticulostriate arteries mainly arise from the posterosuperior aspect of the M1 segment and its remaining vessels arise from the M2 segment. The lateral group of the lateral lenticulostriate arteries have a slightly larger diameter than the medial group. Lateral groups have a recurrent curve before entering the anterior perforated substance. Lateral lenticulostriate arteries make a sharp posterior and medial turn in the cisternal portion from their origin to assume a more lateral curve as they enter the anterior perforated substance. They supply the lateral aspect of the anterior commissure, corona radiata, head and

body of caudate nucleus, lateral segment of globus pallidus, putamen, and superior part of internal capsule [26–28] (Fig. 2.9).

#### 2.4.2 Cortical Branches

The cortical arteries of MCA supply most of the lateral surface of the cerebral hemisphere and are named according to the territory perfused (Fig. 2.10). There are the orbitofrontal artery, prefrontal artery, precentral artery, central artery, anterior parietal artery, posterior parietal artery, and angular artery which supply the upper part of the MCA territory based on Sylvian fissure. The temporooccipital artery, posterior temporal artery, middle temporal artery, anterior temporal artery, and temporopolar artery supply the lower part of the MCA territory.

The orbitofrontal artery supplies the inferior surface of the frontal lobe. The prefrontal artery supplies much of the lateral aspect of the frontal lobe anterior to the sylvian triangle. The orbitofrontal and prefrontal arteries exhibit the fanciful appearance of a candelabra. They usually supply the Broca speech area, the frontal eye fields, and premotor strip on the dominant hemi-



**Fig. 2.10** The cortical branches of middle cerebral artery. (1) Anterior parietal artery; (2) posterior parietal artery; (3) angular artery; (4) temporooccipital artery; (5) posterior temporal artery; (6) middle temporal artery; (7) anterior temporal artery; (8) temporopolar artery; (9) orbitofrontal artery; (10) prefrontal artery; (11) precentral artery; and (12) central artery. Adapted with permission from Essential Neurovascular Anatomy, Copyright Springer Nature [4]

sphere. The precentral artery courses superiorly on the posterior part of the frontal lobe or the anterior edge of the parietal operculum. The central artery courses posterosuperiorly along the central sulcus toward the superior margin of the hemisphere. The anterior parietal artery initially courses along the postcentral sulcus, then courses in the intraparietal sulcus. The posterior parietal artery courses posterosuperiorly and shows the anterior border of the supramarginal gyrus. The angular artery appears at the most posterosuperior portion of the lateral sulcus and crosses transverse temporal gyrus (Heschl's gyrus). The temporooccipital artery courses posteriorly to supply the superior temporal gyrus and lateral surface of the occipital lobe. The posterior temporal artery crosses the superior, middle, and inferior gyrus posteroinferiorly to supply the posterior part of the temporal lobe. The medial temporal artery supplies the middle part of the temporal lobe. The anterior temporal artery that arise from the M1 segment usually supplies the lateral aspect of the anterior temporal lobe.

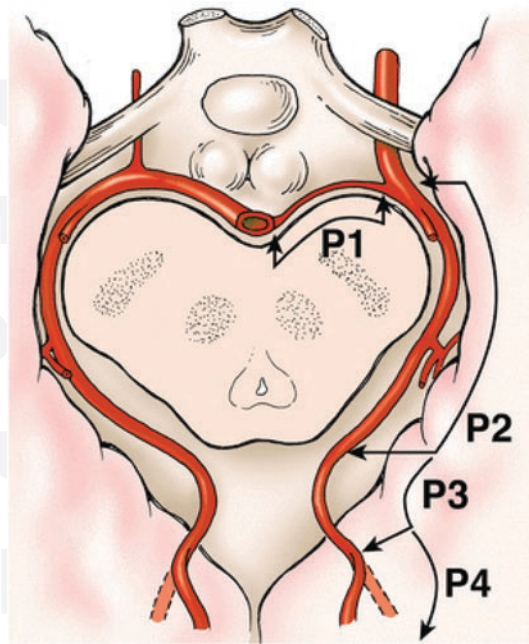
The region named “the watershed zone” occupies the border between the MCA territory and the territories of the adjacent cerebral arteries, meaning that it is at the interface of different circulations. This region is vulnerable to ischemic injury particularly in the hypo-perfused condition.

### 2.4.3 Anomalies of the MCA

Accessory M1 arises from the ACA and parallels the M1. It is associated with aneurysm formation and should be distinguished from other anomalies such as duplicated M1 and a large recurrent artery of Heubner. Duplicated M1 that arises from ipsilateral ICA runs parallel with ipsilateral M1. It is also associated with the aneurysm formation. Fenestration of the M1 is rarely found and should not be misdiagnosed as an M1 dissection.

## 2.5 Posterior Cerebral Artery

The BA is divided into the two PCAs at the front of midbrain, interpeduncular cistern near dorsum sellae or suprasellar cistern below the base of the third ventricle (Fig. 2.11).



**Fig. 2.11** The posterior cerebral artery. Adapted with permission from *Essential Neurovascular Anatomy*, Copyright Springer Nature [4]

The PCA consists of four segments:

- P1: precommunicating segment
- P2: ambient segment
- P3: quadrigeminal segment
- P4: calcarine segment

The P1 segment is a section from basilar bifurcation to the junction with the PComA. It curves around the front of the midbrain in the interpeduncular cistern and locates above the oculomotor nerve. The P2 segment extends from the junction with the PComA to the posterior portion of the midbrain between the midbrain and the hippocampal gyrus. Above the tentorium cerebellum and trochlear nerve, it courses parallel to the basal vein of Rosenthal and optic tract in the ambient cistern. The P3 segment curves medially within the perimesencephalic cistern. Both P3 segments approach each other behind the colliculi with varying distances. Then, it courses laterally from the level of the quadrigeminal plate to the calcarine fissure. The P4 segment begins at the anterior part of the calcarine fissure. It is divided into the medial and lateral occipital arteries within the

calcarine fissure and includes cortical branches that arise from the distal PCA [29].

### 2.5.1 Perforating Branches

The posterior thalamoperforating arteries, up to eight in number, arise from the posterior or superior aspect of the P1 segment (Fig. 2.3). They course posteriorsuperiorly and pass through the posterior perforated substance, the interpeduncular fossa, and the medial walls of the cerebral peduncles. Usually, the posterior thalamoperforating arteries arise from both P1 segments. Both posterior thalamoperforating arteries may arise from one side as a common trunk (the artery of Percheron). In this case, if the common trunk is occluded, thalamic infarction may occur on both sides. The proximal 2–3 mm of the P1 segment are most often free of vessels. Therefore, when treating aneurysm in this area, the risk of perforating artery injury is relatively small.

The thalamogeniculate arteries, 2–12 in number, arise from the posterior or posterosuperior aspect of the P2 segment primarily, as well as the P3 segment [30].

The posterior thalamoperforating arteries and thalamogeniculate arteries together, supply the posteromedial aspect of thalamus, subthalamic nucleus, the substantia nigra, red nucleus, oculomotor and trochlear nuclei, posterior portion of the internal capsule, and the cisternal segment of the oculomotor nerve [9].

The perpendicular perforating arteries arise (up to six in number) from the P1 and P2 segments. They course directly to the cerebral peduncles and supply the corticospinal and corticobulbar tracts, substantia nigra, red nucleus, and tagmental and cisternal portions of the oculomotor nerve.

### 2.5.2 Ventricular Branches

The medial posterior choroidal arteries (PChAs) arise from the P2 segment primarily, but also the P1 segment, or parietooccipital artery. They course around the ambient cistern, then curve

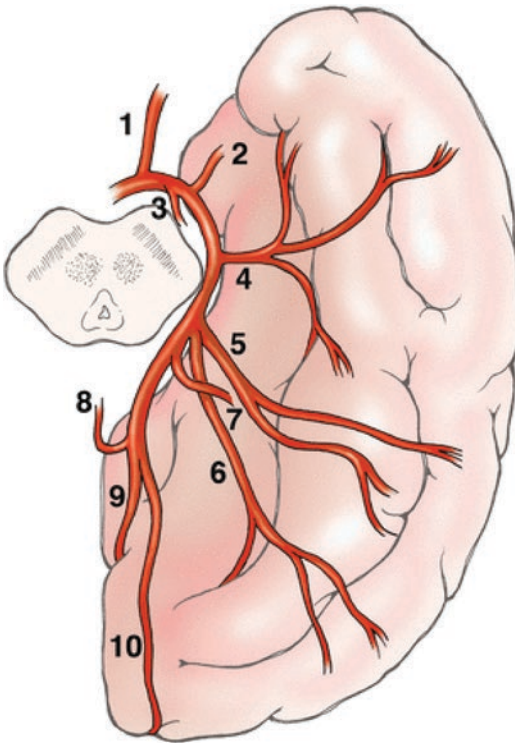
superomedially and run forward to enter the roof of the third ventricle. They extend anteriorly within the velum interpositum toward the foramen of Monro and terminate at the choroid plexus of the lateral ventricle. Cisternal branches of the medial posterior choroidal arteries supply the medial geniculate body, habenula, midbrain, pineal gland, posterior thalamus, and tectal plate.

The lateral PChAs, up to nine in number, arise from the P2 segment or various cortical branches of the PCA. Their origin is more distal than the medial PChAs. They pass through the choroidal fissure to enter the lateral ventricle posteriorly at the level of the atrium. Then, they curve laterally around the pulvinar of the thalamus within the lateral ventricle. The lateral PChAs anastomoses with the medial PChAs and branches of the AChA [31].

### 2.5.3 Cortical Branches

The anterior and posterior temporal arteries arise from the P2 segments (Fig. 2.12). The anterior temporal artery courses anterolaterally under the hippocampal gyrus. The posterior temporal artery courses posterolaterally toward the occipital lobe. They anastomose with temporal branches of the middle cerebral artery and supply the inferior aspect of the temporal lobe. Passing through the calcarine fissure, the posterior cerebral artery is divided into the medial and lateral occipital arteries. The lateral occipital artery is further divided into the anterior, middle, and posterior inferior temporal arteries supplying the inferior surface of the temporal lobe. The medial occipital artery is divided into the parietooccipital artery and the calcarine artery. The parietooccipital artery, the largest terminal branch of the PCA, courses in the parietooccipital sulcus and curves laterally to approach the parietooccipital sulcus. The calcarine artery runs deep within the calcarine sulcus. It supplies the primary visual cortex. The splenic artery arises from the parietooccipital artery or calcarine artery. It anastomoses with the branches of the pericallosal artery and the medial PChA.





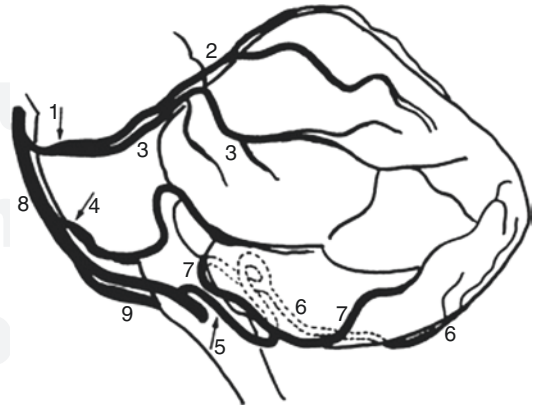
**Fig. 2.12** The major branches of posterior artery. (1) Posterior communicating artery; (2) hippocampal artery; (3) posteromedial choroidal artery; (4) anterior temporal artery; (5) middle temporal artery; (6) posterior temporal artery; (7) posterolateral choroidal artery; (8) splenial artery; (9) parietooccipital artery; and (10) calcarine artery. Adapted with permission from *Essential Neurovascular Anatomy*, Copyright Springer Nature [4]

## 2.6 Basilar Artery

Both VAs join and become the BA at the pontomedullary junction. The BA is approximately 32 mm in length and 4 mm in diameter in adults, until it is divided into two PCAs in the prepontine cistern. It courses along a shallow median groove on the pons.

### 2.6.1 Cerebellar Branches

The SCA arises from proximal portion of the basal bifurcation. It is divided into four segments including the anterior pontomesencephalic, lateral pontomesencephalic, cerebellomesencephalic, and cortical segments (Fig. 2.13). The anterior



**Fig. 2.13** The schematic illustration of the cerebellar arteries. (1) Superior cerebellar artery (SCA); (2) medial branch of SCA; (3) lateral branch of SCA; (4) anterior inferior cerebellar artery (AICA); (5) posterior inferior cerebellar artery (PICA); (6) medial branch of PICA; (7) lateral branch of PICA; (8) basilar artery; and (9) vertebral artery. Adapted with permission from *Vascular Supply and Territories of the Cerebellum*, Copyright Springer Nature [32]

pontomesencephalic segment courses below the oculomotor nerve between the dorsum sellae and the upper brainstem. The lateral pontomesencephalic segment begins at the anterolateral margin of the brain stem, then it curves around the cerebral peduncle posterolaterally below the trochlear nerve and above the trigeminal nerve. It is divided by the tentorium cerebelli at distal portion to form the cerebellomesencephalic segments. It courses within the cerebellomesencephalic fissure and is divided into two cortical branches (medial and lateral). The lateral branch of the SCA supplies superolateral aspect of cerebellar hemisphere, superior cerebellar peduncle, dentate nucleus, and brachium pontis, and the medial branch supplies the superomedial aspect of the cerebellar hemisphere, superior aspect of vermis, inferior colliculi, and midbrain [33].

The AICA arises from the proximal basilar artery and curves laterally, posteriorly, and inferiorly around the pons near the abducens nerve. It is divided into four segments including the anterior pontine, lateral pontine, flocculopeduncular, and cortical segments (Fig. 2.13). The anterior pontine segment is located between the clivus and the belly of the pons. The lateral pontine seg-



ment begins at the anterolateral margin of the pons and passes through the cerebellopontine angle. In this segment, it locates the anteromedial portion of the facial nerve and vestibulocochlear nerve. The flocculopeduncular segment courses above the flocculus and along the middle cerebellar peduncle toward the apex of the cerebellopontine fissure. The cortical segment goes toward the petrosal surface of the cerebellum. The AICA supplies the anterior inferior aspect of the cerebellum, flocculus, middle cerebellar peduncle, inferolateral aspect of pons, and superior portion of medulla. It terminates near the petrosal surface. The labyrinthine artery that mainly arises from the AICA supplies the structures of the internal auditory canal including the facial and vestibulocochlear nerves [34, 35].

### 2.6.2 Perforating Branches

Numerous pontine perforating arteries arise from the BA within the prepontine cistern. The median and paramedian branches arise perpendicularly from the posterior wall of the BA and penetrate the pons posteriorly to reach to the floor of the fourth ventricle. The circumferential branches arise from the posterolateral wall of the basilar artery and curve around the lateral aspect of the pons. They give off many perforating branches perpendicularly to the pons and ventrolateral portion of cerebellum [36].

## 2.7 Vertebral Artery

The VA, which is the first branch of the subclavian artery, is divided into four segments:

- V1: extraosseous segment
- V2: foraminal segment
- V3: extraspinal segment
- V4: intracranial segment

The V1 segment arises from the superior or posterior aspect of the subclavian artery and courses superoposteriorly toward the transverse foramen of the C6. The V2 segment runs verti-

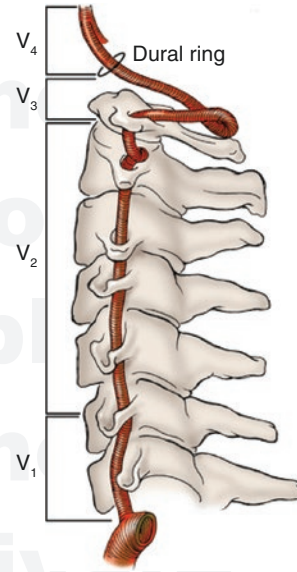
cally to the transverse foramen of the second cervical vertebra and passes through laterally through the transverse foramen of the C2 in an inverted L-shape. Then it turns again superiorly to the transverse foramen of the C1. Passing through the transverse foramen of the C1, the V3 segment makes a posteromedial curve around the atlantooccipital articulation. Then, it turns sharply anteriorly and superiorly to pierce the dura. After piercing the dura, the V4 segment enters the skull via the foramen magnum and each V4 segment joins together at the pontomedullary junction to become the BA. Usually, the left VA is larger in diameter than right one [37].

### 2.7.1 Intracranial Branches

The PICA is the largest and most important vessel among the VA branches and has the most variations. Eighty to ninety percent of the PICA arise from the intracranial VA and the others arise from the extracranial VA. The PICA is divided into five segments and two loops (Fig. 2.13). After separating from the vertebral artery, the PICA curves posteriorly around the inferior margin of the olive within the medullary cistern to be the anterior medullary segment. It runs between or above the root of the glossopharyngeal, vagus, and accessory nerves. The lateral medullary segment courses between the accessory rootlets. The tonsillomedullary segment extends from the level of accessory nerves around the caudal half of the tonsil and forms the caudal loop. The telovelotonsillar segment extends from the midlevel of the tonsil to the exit from the cleft located between the tela choroidea and inferior medullary velum superiorly and the superior pole of the tonsil inferiorly, and forms a cranial loop. Then, it terminates upon separating into the vermian branch (medial branch) and the tonsilohemispheric branch (lateral branch). The PICA supplies the lower medulla and the inferior aspects of the fourth ventricle, tonsils, vermis, and inferolateral cerebellar hemisphere. If territories of the PICA are occluded, a lateral medullary syndrome or Wallenberg syndrome is generated. Numerous medullary perforating

branches arise from the anterior, lateral, posterior medullary segments. Therefore, medullary functions can be spared in case of more distal PICA infarctions [38].

The anterior spinal artery arises from the V4 segment. Each anterior spinal artery courses inferomedially to unite with each other. After combining, it descends along the anteromedian sulcus of the spinal cord. The anterior spinal artery gives off small perforating vessels to the anterior aspect of the medulla and anterior two thirds of the spinal cord. The lateral spinal artery arises from the V4 segment or posterior inferior cerebellar artery. It originates lateral to the medulla, and descends anterior to the posterior spinal nerve roots and posterior to the dentate ligament. It supplies the accessory nerve, the lateral and posterior aspects of medulla and spinal cord, and C1–4 spinal nerves.



**Fig. 2.14** The vertebral artery. Adapted with permission from *Essential Neurovascular Anatomy*, Copyright Springer Nature [4]

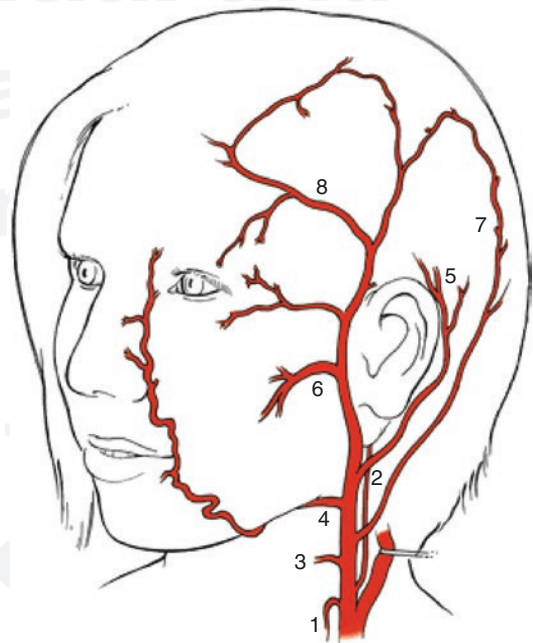
## 2.8 External Carotid Artery

The ECA is anatomically related to many important structures of the head and neck. Initially, it locates at the anterior and medial portion of the ICA. Running cranially, it is in the posterolateral portion of the ICA to ramify over the structures of the face (Fig. 2.14).

The ECA consists of eight main arteries which include the superior thyroid artery, ascending pharyngeal artery, lingual artery, facial artery, occipital artery, posterior auricular artery, internal maxillary artery, and superficial temporal artery.

### 2.8.1 Superior Thyroid Artery

The superior thyroid artery is the first branch of the ECA. It courses inferiorly to anastomose with the branches of the contralateral superior thyroid artery and ipsilateral inferior thyroid artery and supplies the thyroid gland, parathyroid gland, larynx, and related structures (Fig. 2.15).



**Fig. 2.15** The branches of external carotid artery. (1) Superior thyroid artery; (2) ascending pharyngeal artery; (3) lingual artery; (4) facial artery; (5) posterior auricular artery; (6) maxillary artery; (7) occipital artery; and (8) superficial temporal artery. Adapted with permission from *Essential Neurovascular Anatomy*, Copyright Springer Nature [4]

### 2.8.2 Ascending Pharyngeal Artery

The ascending pharyngeal artery arises from the posterior portion of the proximal ECA or arises from the cervical segment of the ICA. It occasionally has a common trunk with the occipital artery. The ascending pharyngeal artery is divided into the pharyngeal trunk, neuromeningeal trunk, inferior tympanic branch, and musculospinal branch.

The pharyngeal trunk consists of the superior, middle, and inferior pharyngeal branches, and supplies the nasopharynx, oropharynx, and hypopharynx, respectively. The superior pharyngeal branch passes through the artery of foramen rotundum to anastomose with the inferolateral trunk of the ICA.

The neuromeningeal trunk consists of the hypoglossal and jugular branches. The hypoglossal branches supply the neural structure of the hypoglossal canal and various dural territories of the posterior fossa, and have bilateral connections between the vertebral artery and the ascending pharyngeal artery behind the C2 body (arcade of the odontoid process). Furthermore, they form the collateral anastomosis with the meningohypophyseal artery. The jugular branches enter through the jugular foramen and run posterolaterally. It supplies the adjacent dura and sends branches running along the course of the sigmoid sinus.

The inferior tympanic artery courses between the pharyngeal trunk and the neuromeningeal trunk. It anastomoses with the stylomastoid branch of the occipital artery running with the facial nerve, middle meningeal artery, and caroticotympanic branch of the ICA in the middle ear.

The musculospinal branch supplies the accessory nerve, superior sympathetic ganglion, and cervical muscle and anastomoses with the vertebral artery, ascending cervical artery, and deep cervical arteries.

### 2.8.3 Lingual Artery

The lingual artery is the second branch of the ECA coursing anteriorly. It supplies the tongue, mouth floor, and suprahyoid area. Ten percent

of the lingual artery makes a common linguofacial trunk with the facial artery. The facial artery and lingual artery achieve hemodynamical balance. Therefore, if one is hypoplastic, the other will be prominent to supplement the lack of blood flow.

### 2.8.4 Facial Artery

The facial artery is the third branch moving toward the anterior direction that arises from a just distal portion to the origin of the lingual artery. It courses inferolaterally around the body of the mandible. Then, it turns anterosuperiorly to supply the face, palate, lip, and cheek. The facial artery maintains hemodynamic balance with the branches of the ECA such as the ascending pharyngeal artery, internal maxillary artery, and accessory meningeal artery. Because it anastomoses with the branch of the ophthalmic artery branch, it can be an important supplementary collateral in case of occlusion of the ipsilateral ICA.

### 2.8.5 Occipital Artery

The occipital artery is one of the posteriorly directed branches of the ECA and it courses posterolaterally between the occipital bone and C1 vertebra to supply the extensive musculocutaneous structures, meninges, and scalp.

Normally, the occipital artery anastomoses with the ipsilateral vertebral artery in the C1 and C2 spaces and with the deep cervical artery at the C3 and C4 level. Sometimes, there is a connection between the musculospinal branch of the ascending pharyngeal artery.

Among the branches of the occipital artery, the stylomastoid artery and transmastoid artery are the endocranial branches. As the stylomastoid artery supplies the facial nerve and structures in the middle ear, caution is needed during embolization. The transmastoid artery is the source of high flow vascular lesions or tumors in the posterior fossa.

### 2.8.6 Posterior Auricular Artery

The posterior auricular artery courses posteriorly and arises from distal portions of the occipital artery to supply the superficial structures of the outer ear such as the scalp around the ear, ear, and external auditory meatus. Sometimes, it ramifies the stylomastoid artery that supplies the chorda tympani nerve.

### 2.8.7 Superficial Temporal Artery

The superficial temporal artery is the thermal artery that supplies the frontal and parietal areas of the scalp, ear, lateral aspect of the orbit and parotid gland. Sometimes, it has important anastomoses with the palpebral and lacrimal arteries.

### 2.8.8 Internal Maxillary Artery

The internal maxillary artery is the largest ECA branch. It terminates by ramifying numerous branches that supply structures deep in the face and nose, within the pterygopalatine fossa. The middle meningeal artery that arises from the proximal portion of the internal maxillary artery is the largest branch. It enters the skull via the foramen spinosum by curving at a right angle and supplying the dura of the frontal, temporal squamous, parietal area and near the sigmoid and transverse sinuses. The accessory meningeal artery is a small but important branch that arises from the middle meningeal artery. It passes through the foramen ovale or sphenoid emissary foramen to enter the cranial space. It mainly supplies the extracranial structures and additionally the trigeminal ganglion, cavernous sinus, and adjacent dura near the foramen ovale. It anastomoses with the inferolateral trunk of the ICA. The sphenopalatine artery passes through the foramen spinosum to supply the nose. It is mainly associated with posterior epistaxis. The distal branches of the internal maxillary artery including the artery of the foramen rotundum, the vidian artery, and the palatovaginal arteries have numerous

anastomoses with other ECA branches and the ICA and its branches.

## References

1. Parent A, Carpenter M. Carpenter's human neuroanatomy. Baltimore, MD: Williams & Wilkins; 1995.
2. Vitek JJ, Reaves P. Thoracic bifurcation of the common carotid artery. *Neuroradiology*. 1973;5(3):133–9.
3. Kerber C, Knox K, Hecht S, et al. Flow dynamics in the human carotid bulb. *AJNR Am J Neuroradiol*. 1996;2:422–9.
4. Harrigan MR, Deveikis JP. Essential Neurovascular Anatomy. In: Handbook of cerebrovascular disease and neurointerventional technique. Contemporary medical imaging. Cham: Humana Press; 2018.
5. Bouthillier A, van Loveren HR, Keller JT (1996) Segments of the internal carotid artery: a new classification. *Neurosurgery*. 38(3):425–32; discussion 32–3.
6. von Overbeeke JJ, Dujovny M, Dragovic L et al (1991) Anatomy of the sympathetic pathways in the carotid canal. *Neurosurgery*. 29(6):838–43; discussion 43–4.
7. Alderson LM, Noonan PT, Choi IS, Henson JW. Regional subacute cranial neuropathies following internal carotid cisplatin infusion. *Neurology*. 1996;47(4):1088–90.
8. Hayreh SS. The ophthalmic artery: III. Branches. *Br J Ophthalmol*. 1962;46(4):212–47.
9. Schmahmann JD. Vascular syndromes of the thalamus. *Stroke*. 2003;34(9):2264–78.
10. Alpers BJ, Berry RG, Paddison RM. Anatomical studies of the circle of Willis in normal brain. *AMA Arch Neurol Psychiatry*. 1959;81(4):409–18.
11. Bisaria KK. Anomalies of the posterior communicating artery and their potential clinical significance. *J Neurosurg*. 1984;60(3):572–6.
12. Hupperts RM, Lodder J, Heuts-van Raak EP, et al. Infarcts in the anterior choroidal artery territory. Anatomical distribution, clinical syndromes, presumed pathogenesis and early outcome. *Brain*. 1994;117(Pt 4):825–34.
13. Luh GY, Dean BL, Wallace RC, et al. The persistent fetal carotid-vertebrobasilar anastomoses. *Am J Roentgenol*. 1999;172(5):1427–32.
14. Perlmutter D, Rhoton AL Jr. Microsurgical anatomy of the anterior cerebral-anterior communicating-recurrent artery complex. *J Neurosurg*. 1976;45(3):259–72.
15. Perlmutter D, Rhoton AL Jr. Microsurgical anatomy of the distal anterior cerebral artery. *J Neurosurg*. 1978;49(2):204–28.
16. VanderArk GD, Kempe LC. Classification of anterior communicating aneurysms as a basis for surgical approach. *J Neurosurg*. 1970;32(3):300–3.
17. Hassan T, Elsayed A, Abbas M, et al. Proposed parent vessel geometry based classification of anterior



- communicating artery-located aneurysms. *World Neurosurg.* 2017;101:259–69.
18. Falougy EL, Selmeciova H, Haviarova Z, et al. The variable origin of the recurrent artery of heubner: an anatomical and morphometric study. *Biomed Res Int.* 2013;2013:873434.
  19. Suzuki M, Onuma T, Sakurai Y, et al. Aneurysms arising from the proximal (A1) segment of the anterior cerebral artery. A study of 38 cases. *J Neurosurg.* 1992;76(3):455–8.
  20. Dunker RO, Harris AB. Surgical anatomy of the proximal anterior cerebral artery. *J Neurosurg.* 1976;44(3):359–67.
  21. Webster JE, Gurdjian ES, Lindner DW, et al. Proximal occlusion of the anterior cerebral artery. *Arch Neurol.* 1960;2:19–26.
  22. Choudhury AR (1976) Proximal occlusion of the dominant anterior cerebral artery for anterior communicating aneurysm. *J Neurosurg.* 45(5):484–90.
  23. Gibo H, Carver CC, Rhoton AL Jr, et al. Microsurgical anatomy of the middle cerebral artery. *J Neurosurg.* 1981;54(2):151–69.
  24. Umansky F, Juarez SM, Dujovny M, et al. Microsurgical anatomy of the proximal segments of the middle cerebral artery. *J Neurosurg.* 1984;61(3):458–67.
  25. Hernesniemi J, Dashti R, Niemela M, et al. Microsurgical and angiographic anatomy of middle cerebral artery aneurysm. *Neurosurgery.* 2010;66(5):E1030.
  26. Herman LH, Ostrowski AZ, Gurdjian ES. Perforating branches of the middle cerebral artery. An anatomical study. *Arch Neurol.* 1963;8:32–4.
  27. Marinkovic SV, Milisavljevic MM, Kovacevic MS, et al. Perforating branches of the middle cerebral artery. Microanatomy and clinical significance of their intracerebral segments. *Stroke.* 1985;16(6):1022–9.
  28. Umansky F, Gomes FB, Dujovny M, et al. The perforating branches of the middle cerebral artery. A micro-anatomical study. *J Neurosurg.* 1985;62(2):261–8.
  29. Zeal AA, Rhoton AL Jr. Microsurgical anatomy of the posterior cerebral artery. *J Neurosurg.* 1978;48(4):534–59.
  30. Milisavljevic MM, Marinkovic SV, Gibo H et al (1991) The thalamogeniculate perforators of the posterior cerebral artery: the microsurgical anatomy. *Neurosurgery.* 28(4):523–29; discussion 9–30.
  31. Neau JP, Bogousslavsky J. The syndrome of posterior choroidal artery territory infarction. *Ann Neurol.* 1996;39(6):779–88.
  32. Wang Q, Caplan LR. Vascular supply and territories of the cerebellum. In: *Essentials of cerebellum and cerebellar disorders.* Cham: Springer; 2016.
  33. Hardy DG, Peace DA, Rhoton AL Jr. Microsurgical anatomy of the superior cerebellar artery. *Neurosurgery.* 1980;6(1):10–28.
  34. Naidich TP, Kricheff II, George AE, et al. The normal anterior inferior cerebellar artery. Anatomic-radiographic correlation with emphasis on the lateral projection. *Radiology.* 1976;119(2):355–73.
  35. Naidich TP, Kricheff II, George AE, et al. The anterior inferior cerebellar artery in mass lesions. Preliminary findings with emphasis on the lateral projection. *Radiology.* 1976;119(2):375–83.
  36. Torche M, Mahmood A, Araujo R, et al. Microsurgical anatomy of the lower basilar artery. *Neurol Res.* 1992;14(3):259–62.
  37. Akar ZC, Dujovny M, Slavin KV, et al. Microsurgical anatomy of the intracranial part of the vertebral artery. *Neurol Res.* 1994;16(3):171–80.
  38. Lister JR, Rhoton AL Jr, Matsushima T, et al. Microsurgical anatomy of the posterior inferior cerebellar artery. *Neurosurgery.* 1982;10(2):170–99.

should not be  
copied, distributed or  
reproduced in whole  
or in part, nor passed  
to any third party.