This document is copyright of the original publisher. This document is strictly private, confidential and personal to its recipients and should not be copied, distributed or reproduced in whole or in part, nor passed to any third party.

12 Hemorrheologic Disease

Min Kyoung Kang

Abstract

How do you think we know hemorrheologic disease-related stroke? In most situations, patients and clinician have low awareness of hemorrheologic disease-related stroke because of its low incidence and uncertainty of diagnosis. However, considering the importance and the curability of the disease, up-to-date knowledge about pathophysiology and important differential points between classical stroke and hemorrheologic disease-related stroke are essential for neurologists. In this context, understanding the key concept of hemorrheologic disease will provide appropriate treatment strategy according to its pathophysiology. At each point, antiphospholipid syndrome must be checked for, especially in young stroke patients with undetermined etiologies. An expert's opinion is needed on the diagnosis of cancer-related stroke and cerebral venous thrombosis based on patients' clinical context and stroke pattern. For the diagnosis of other hemorrheologic diseases, the clinician needs to watch out for any laboratory clues. The emerging treatment option for hemorrheologic disease is non-vitamin K antagonist oral anticoagulants; however, prospective studies are needed to prove its efficiency for hemorrheologic disease-related stroke. Through the delicate suspicion of the clinician, we could reduce a patient's fear of uncertainty of diagnosis and recurrence in the long term.

12.1 Antiphospholipid Syndrome

Since the first report in Jamaica, understanding of the pathophysiology of antiphospholipid syndrome (APS) has been pursued for more than three decades, but it is still not totally understood. A typical APS has several established characteristics, such as arterial and venous thromboses, pregnancy-related morbidity, miscarriages, fetal growth restriction and deaths, and pre-eclampsia [1]. In fact, APS can be associated with various clinical symptoms, such as stroke, seizures, cognitive impairment, pulmonary embolism, heart disease, coronary artery disease, thrombocytopenia, livedo reticularis, osteonecrosis, renal failure, and distal gangrene (Fig 12.1). This autoimmune disease is diagnosed by certain types of autoimmune antibodies, not mutually exclusive but commonly referred to as antiphospholipid antibodies, such as lupus anticoagulant (LA), anticardiolipin antibodies (aCL), and anti-β2-glycoprotein I (GPI) antibodies. Among these antibodies, the prelude to the coagulation cascade is binding to β2-GPI. Despite the high interest for APS, there are no robust epidemiological statis-

M. K. Kang (✉)
Department of Neurology, Seoul National University Hospital, Seoul, Republic of Korea

© Springer Science+Business Media Singapore 2020
S.-H. Lee (ed.), *Stroke Revisited: Pathophysiology of Stroke*, Stroke Revisited,
https://doi.org/10.1007/978-981-10-1430-7_12

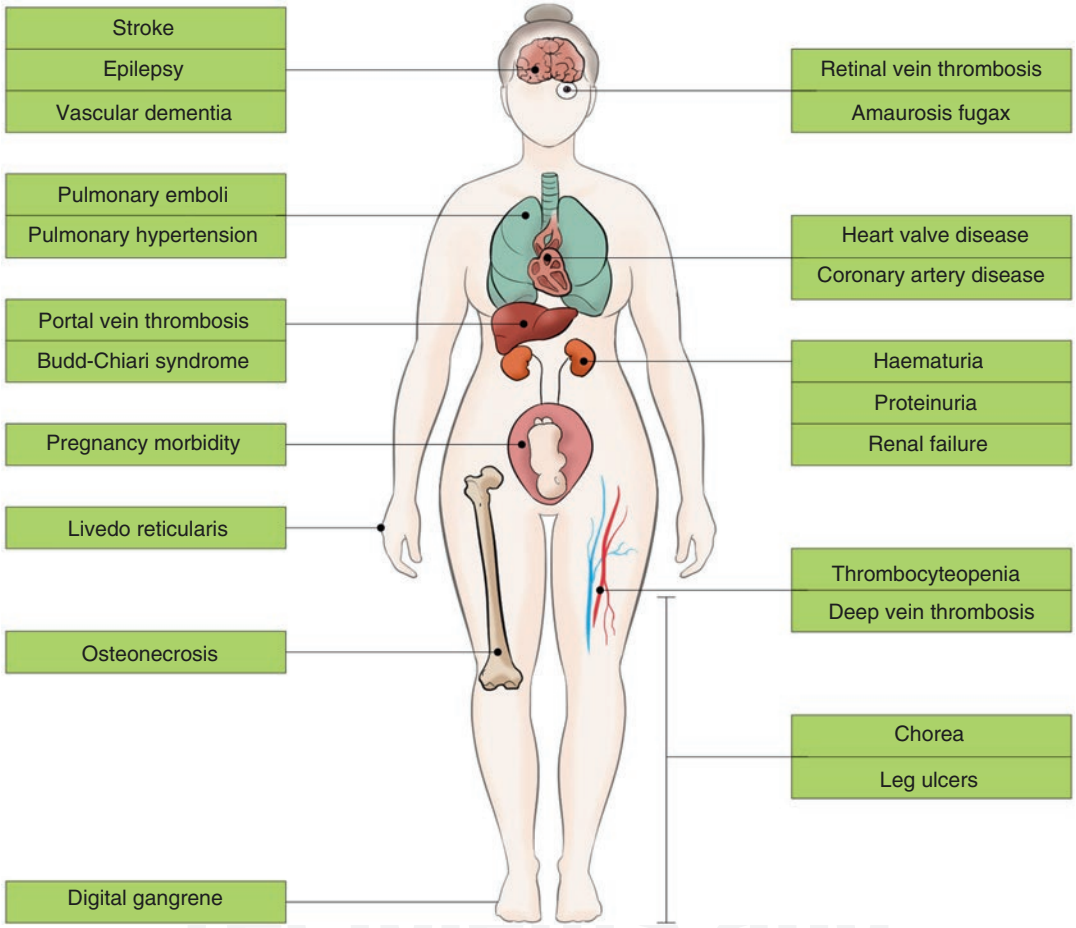

Fig. 12.1 Clinical manifestations of antiphospholipid syndrome. Adapted with permission from Nature Review Disease Primers, Copyright Springer Nature [1]

tics, as the methods of antibody detection are not established among worldwide laboratories.

12.1.1 Epidemiology of APS

There are no clear statistics on the epidemiology of APS, but the reported incidence of APS is 5 per 100,000 individuals per year, and its prevalence is approximately 40–50 cases per 100,000 individuals [2]. Despite efforts made to standardize immunoassays for the detection of antiphospholipid antibodies, considerable variations in interassay and interlaboratory aspects are still reported. For this reason, the robustness of epidemiological data of antiphospholipid antibody positivity and APS in the general population is limited.

In the cohort of the Euro-Phospholipid project, which started in 1999 as a multicenter, prospective study, approximately 5% of the total cohort experienced stroke and transient ischemic attacks. Interestingly, some studies showed that antiphospholipid antibodies were detected in 20% of young stroke cases. Specifically, 40% of the participants of the Euro-Phospholipid project had deep vein thrombosis, 20% had stroke, 14.1% had pulmonary embolism, and 11.1% had transient ischemic attack and obstetric morbidity [3].

This document is copyright of the original publisher. This document is strictly private, confidential and personal to its recipients and should not be copied, distributed or reproduced in whole or in part, nor passed to any third party.

12.1.2 Pathophysiology of APS

APS is an autoimmune disease that is usually caused by autoantibodies, such as LA, aCL, and anti-β2-GPI antibodies. Binding of antiphospholipid antibodies leads to dimerization of β2-GPI that enhances activation of inflammatory cells and endothelial cells, promotion of coagulation, and activation of complement system (Fig. 12.2) [4]. Autoantibodies bound to β2-GPI, especially via domain 1, can induce a strong prothrombogenic tendency in animal models through the injection of human anti-β2-GPI antibodies in mice. Through this process, the cascade through platelet and complement activation to the monocyte and vascular environment becomes the main route to thrombosis in APS.

In the two-hit theory, the first hit is the genetic predisposition to produce autoantibodies bound to β2-GPI. Although autoantibodies are always produced, signs and symptoms of APS do not always manifest [1]. The second hit is the trigger for promoting the production of autoantibodies. Inflammation, infection, smoking, pregnancy, and other procoagulant factors such as contraceptives, smoking, and surgery have all been reported as potential causes of the second hit (Fig. 12.2). Molecular mimicry between structures of infectious agents such as bacteria or viruses and β2-GPI-derived amino acid sequences is thought to be the cause of the formation of autoantibodies. In this context, it is better to see autoimmune antibodies collectively, as indicated by the term antiphospholipid antibodies, rather than highlighting each identity.

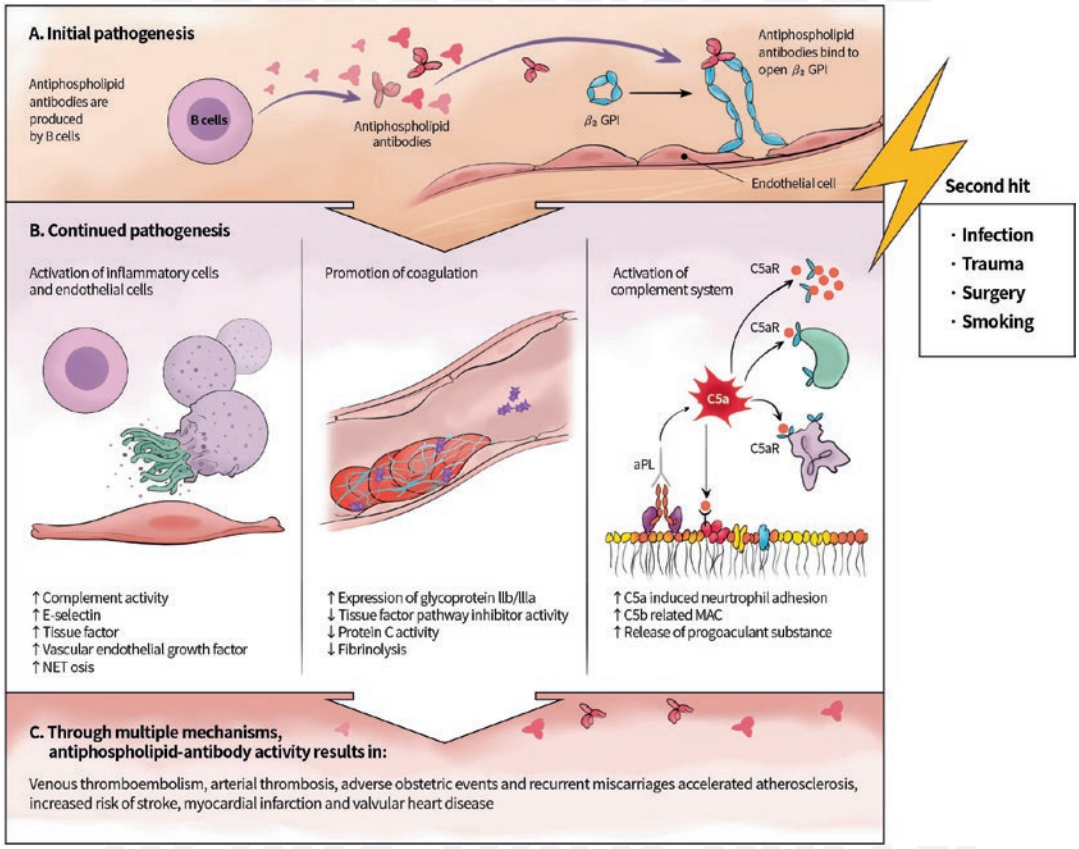

Fig. 12.2 Pathophysiology of antiphospholipid syndrome. Adapted with permission from New England Journal of Medicine, Copyright Massachusetts Medical Society [4]

This document is copyright of the original publisher. This document is strictly private, confidential and personal to its recipients and should not be copied, distributed or reproduced in whole or in part, nor passed to any third party.

This document is copyright of the original publisher. This document is strictly private, confidential and personal to its recipients and should not be copied, distributed or reproduced in whole or in part, nor passed to any third party.

12.1.3 Diagnosis of APS

APS could be diagnosed by an expert clinician who evaluates the patient's history and laboratory test comprehensively. Definitive diagnosis of APS follows a set of classification criteria (Table 12.1). However, the symptoms that do not fit with the criteria for definite APS need to be assessed in detail. These symptoms may also indicate thrombocytopenia, hemolytic anemia, thrombotic microangiopathy, valvular heart lesion, livedo reticularis, cognitive dysfunction, subcortical white-matter change, multiple sclerosis, chorea, or myelopathy. For laboratory criteria, assessment of antibody profile is the mainstay of diagnosis and helps in risk stratification of APS. High titer and detection of multiple autoantibodies provide more confidence in the diagnosis.

However, obtaining definitive APS diagnosis has several hurdles. First, there is a problem on the standardization of immunoassays for measurement of antiphospholipid antibodies. Profound interassay and interlaboratory variations are still reported. Considering the difference among laboratories, the diagnosis criteria were set at ≥99% for antibody titer for aCL. Second, in anticoagulated patients, a false positive is possible. Third, for exclusion of transient humoral change, the restriction sentence, "two positive results at least 12 weeks apart between tests" was included in the diagnostic criteria for APS. If an aCL result for only a single time point is available, the diagnosis may be delayed. Thus, integrated interpretation of all tests and symptoms is needed for APS diagnosis.

Table 12.1 Diagnosis of antiphospholipid syndrome

Clinical criteria (one or more) 1. Vascular thrombosis: One or more objectively confirmed episodes of arterial, venous, or small vessel thrombosis occurring in any tissue or organ 2. Pregnancy morbidity: (a) One or more unexplained deaths of a morphologically normal fetus at or beyond the 10th week of gestation (b) One or more premature births of a morphologically normal neonate before the 34th week of gestation due to eclampsia, preeclampsia, or placental insufficiency (c) Three or more unexplained consecutive spontaneous abortions before the 10th week of gestation
Laboratory criteria (one or more, present in two or more occasions at least 12 weeks apart using recommended procedures) 1. Lupus anticoagulant, detected according to the guidelines of the International Society on Thrombosis and Hemostasis 2. Anticardiolipin antibody of IgG and/or IgM isotype, present in a medium or high titer (greater than 40 GPL or MPL or greater than the 99th percentile), measured by a standardized ELISA 3. Anti-β2-glycoprotein-1 antibody of IgG and/or IgM isotype, present in a titer greater than the 99th percentile, measured by a standardized ELISA

12.1.4 Treatment of APS Treatment

APS is a relatively rare disease, and its evidence is scarce. The treatment decision was made based on expert opinion in many cases. Under the current diagnostic system that consists of symptoms and a special laboratory test, the primary prevention of APS is a great challenge. As a conventional cardiovascular risk factor, smoking cessation was recommended, and low-dose aspirin and hydroxychloroquine can be considered for patients with systemic lupus erythematosus (SLE) who are positive for LA. For secondary prevention for those who experienced a thromboembolic event, aspirin was recommended as evidence level A. Considering that platelet activation is one of the pathways of APS, aspirin is a reasonable option. However, oral anticoagulants, warfarin or non-vitamin K antagonist oral anticoagulants (NOAC), might have a role in the coagulation pathway and tissue factors pathway, especially in the refractory group (Table 12.2).

NOAC can be an emerging treatment option considering the mechanism of thrombosis in APS and the ease of use. Rivaroxaban was compared to warfarin in a multicenter randomized controlled trial [5]. In this trial, the peak thrombin generation was lower in the rivaroxaban group than in the warfarin group, which leads to the extension of the beneficial effect of warfarin to NOAC. Anti-inflammatory drugs, such as intravenous immunoglobulin, rituximab, eculizumab, and hydroxychloroquine, are also being studied in APS.

Table 12.2 Treatment of antiphospholipid syndrome

Clinical manifestation	Treatment
Venous thrombosis	Oral anticoagulation therapy (INR 2.0–3.0)
Arterial thrombosis	Oral anticoagulation therapy (INR 3.0–4.0) or LDA plus oral anticoagulation therapy (INR 2.0–3.0) or LDA alone
Antiphospholipid positivity with previous thrombosis	LDA plus therapeutic dose of LMHW
Pregnancy with antiphospholipid positivity	Prophylactic dose of LMWH for 6 weeks postpartum
Treatment-refractory antiphospholipid syndrome	Increased intensity of anticoagulation therapy (INR > 3.0) or add LDA, hydroxyquine or rituximab to oral anticoagulation

LDA low-dose aspirin, *LMWH* low molecular weight heparin

12.2 Cancer-Related Stroke

Since the declaration of war on cancer, many advances have been made in cancer treatment and diagnosis, but humans have not yet been able to conquer cancer. As the number of people with cancer increases, the incidence of cancer-related stroke has also increased. Moreover, as the duration of cancer is lengthening according to increased life expectancy, the incidence of cancer-related stroke has also increased.

Patients with cancer are at risk for the development of ischemic stroke. Malignancy activates the coagulation cascade by multiple mechanisms, by itself, and by treatment such as chemotherapy, radiotherapy, and surgery. Multiple site infarction and increased D-dimer level help in the diagnoses of cancer-related stroke. Low-molecular-weight heparin (LMWH) is thought to be the drug of choice, but there are emerging NOACs for cancer-related stroke. The diminished general medical condition of patients and this mechanistic uncertainty make it difficult to choose treatment options; hence, the expert needs to weigh the benefits and risks of treatment for cancer-related stroke.

12.2.1 Epidemiology of Cancer-Related Stroke

Cancer-related thrombosis was first described in 1876. Since then, many advances in diagnostic and therapeutic technology enable to extend the life expectancy of cancer patients. At present, 40% of the general population is likely to develop any type of cancer throughout their lifetime [5]. In addition, the survival rate of cancer patients has increased by 1.5 times compared to that at 10 years ago. Therefore, the management of cancer complications has become more interesting and important. Approximately 10% of in-hospital ischemic stroke patients have comorbid cancer, and cancer is also associated with early neurological deterioration, poor functional outcome, stroke recurrence rate, and mortality after stroke [6]. In a different light, approximately 7% of cancer patients experienced a twofold increased risk of ischemic stroke at 1 year since diagnosis. The most common type of cancer in patients with stroke and active cancer are lung, gastrointestinal, and breast cancer. The incidence of stroke correlates with advanced cancer stage, the highest in stage 4. Besides stroke, the manifestation of cancer-associated thrombosis includes pulmonary embolism, deep vein thrombosis, and non-bacterial thrombotic endocarditis (NBTE). Recently, many cancer patients live longer and have more therapeutic options; thus, cancer-related stroke becomes more important.

12.2.2 Pathophysiology of Cancer-Related Stroke

The exact pathophysiology of cancer-related stroke remains unknown. However, we think that it may be a multifactorial phenomenon. The following are considered key players: hypercoagulability by cancer itself; tumor microparticles and mucin circulating in the bloodstream; induced hypercoagulability by cancer that correlated with cancer type (highest in adenocarcinoma), advanced stage, and vessel invasion; tissue factor and procoagulant factor released by cancer cell; activated platelet, endothelial cell, and adhesion

This document is copyright of the original publisher. This document is strictly private, confidential and personal to its recipients and should not be copied, distributed or reproduced in whole or in part, nor passed to any third party.

molecules such as P- and L-selectin; neutrophil extracellular trap (NET) generated by stimulated neutrophil and inflammatory cytokines such as tumor necrosis factor (TNF), interleukin (IL)-1 and IL-6 produced by monocyte or macrophage are proposed to initiate the coagulation cascade of cancer-related stroke (Fig. 12.3). In addition, cancer patients have worsened classical risk factors of stroke. Systemic inflammation evoked by cancer promotes atherosclerotic plaque progression and rupture. A rare but important mechanism in cancer patients is increased embolic tendency due to atrial fibrillation or septic embolism.

Another key player is anticancer treatment. L-asparaginase for acute lymphoblastic leukemia, alkylating agent (cisplatin), mammalian target of rapamycin (mTOR) inhibitor (everolimus, temsirolimus), proteasome inhibitors (bortezomib), monoclonal antibodies (bevacizumab), vascular endothelial growth factor-receptor (VEGF)-targeted therapy (aflibercept), tyrosine kinase inhibitor (sorafenib, sunitinib, pazopanib, axitinib, cabozantinib, lenvatinib, nilotinib, ponatinib), interferon-alpha, anti-estrogen treatment (raloxifene, tamoxifen), and radiotherapy are known to increase the risk of stroke [7]. They mainly evoke endothelial dysfunction. The VEGF pathway is a relatively well-documented mechanism of anticancer therapy. Inhibition of VEGF receptor hinders nitric oxide (NO) production by endothelial NO synthase via the phosphoinositide-3-kinase-protein kinase B/Akt pathway. Radiotherapy can also worsen atherosclerotic changes [8].

An interesting pathologic finding related to tumor is NBTE. NBTE presents as sterile eosinophilic vegetation or wartlike materials made of fibrin and platelet aggregates. It is believed to be caused by inflammation or a microorganism, but not by bacteria [5].

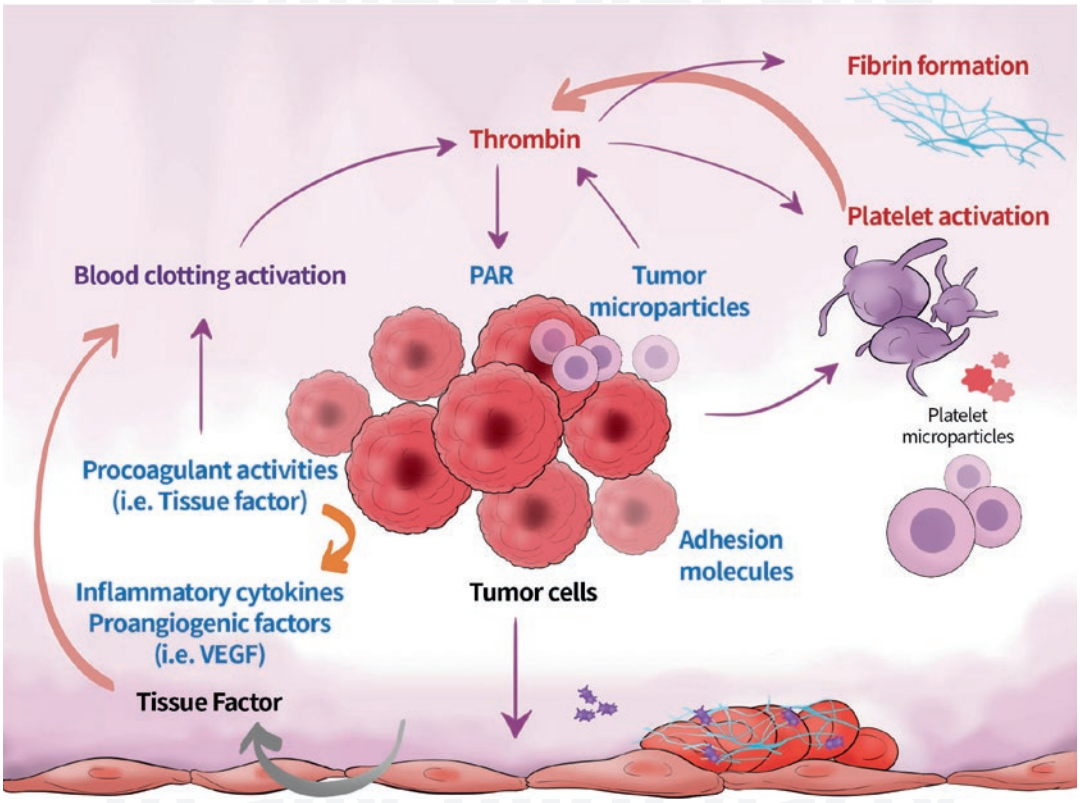

Fig. 12.3 Pathophysiology of cancer-related stroke. *PAR* protease-activated receptors, *VEGF* vascular endothelial growth factor

This document is copyright of the original publisher. This document is strictly private, confidential and personal to its recipients and should not be copied, distributed or reproduced in whole or in part, nor passed to any third party.

12.2.3 Diagnosis of Cancer-Related Stroke

There are no definite diagnostic criteria for cancer-related stroke. Therefore, when a stroke occurs in a cancer patient, the clinician must concentrate on the mechanism of stroke by careful consideration of the clinical settings: time from cancer diagnosis, cancer cell type, history of anticancer treatment, ischemic lesion, and laboratory tests. Proposed clues for cancer-related stroke include increased D-dimer level, C-reactive protein, fibrinogen, tumor marker, decreased platelet count, fibrinogen or hematocrit, multiple brain lesions that cannot be explained by single vessel territory, and echocardiographic evidence of NBTE [9]. Neurologists may obtain additional clues from transcranial doppler (TCD) imaging. In a prospective study, 50% of cancer-related stroke patients had signals of microemboli detected on TCD exams [10]. In addition, the presence of the microemboli was associated with high D-dimer levels. It suggests an active hypercoagulable state in many of these patients.

12.2.4 Treatment of Cancer-Related Stroke

The primary principle for the treatment of cancer-related stroke is the use of a precise approach. There is no concrete consensus on the management of cancer-related stroke, and their management slightly differed from other ischemic stroke patients. First, cancer must be eradicated as soon as possible. As described above, the key player is the cancer cell itself. Second, the clinician should prescribe medical treatment when the benefit of anticoagulation could surpass the risk of bleeding, considering underlying general medical condition and life expectancy. Third, the clinician should ensure that the prescribed treatment is the most appropriate method for the patient. For example, oral medication would not be appropriate for patients with obstruction of gastrointestinal tract due to cancer.

What medication is appropriate for this patient? Considering the main pathophysiology, anticoagulation could be a proper option; hence, warfarin and LMWH have been used thus far (Table 12.3). However, for many practical reasons such as consistency of the anticoagulant effect and the ease of administration, NOACs are emerging candidates for long-term coagulation [8]. Regarding cancer-associated venous thromboembolisms (VTE), research of NOAC uses for cancer-related thrombosis has been conducted. Edoxaban, rivaroxaban, and apixaban led to less recurrent thromboembolism but more events of major bleeding compared to LWMH. However, data on the utility of NOACs for cancer-related stroke is limited. An alternative for cancer-related stroke is antiplatelet therapy. Platelets activated by cancer itself or factors secreted by cancer play a role in cancer-related stroke, so antiplatelet agents might have a protective effect for cancer-related stroke properties. However, antiplatelet therapy has not been proven effective for the secondary prevention of cancer-associated stroke.

Table 12.3 Treatment of cancer-related stroke

Acute management	
LMWH	Dalteparin 200 U/kg QD Enoxaparin 1 mg/kg BID
Fondaparinux	5 mg (<50 kg), 7.5 mg (50–100 kg), 10 mg (>100 kg) QD
Unfractionated heparin	APTT-adjusted infusion (target APTT 2–2.5 X control)
Chronic management	
LMWH	Recommended for first 6 months as monotherapy Without warfarin in patients with proximal DVT or PE and metastatic or advanced cancer
NOACs	Minimum 3 months

LMWH low molecular weight heparin, *DVT* deep vein thrombosis, *PE* pulmonary embolism, *NOAC* non-vitamin K antagonist oral anticoagulants

12.3 Cerebral Venous Thrombosis

Cerebral venous thrombosis (CVT) is caused by thrombosis, and its incidence is lower than strokes of other etiologies. Its vague neurologic symptoms and signs, such as headache, visual disturbance, and seizures, pose diagnostic challenges to clini-

This document is copyright of the original publisher. This document is strictly private, confidential and personal to its recipients and should not be copied, distributed or reproduced in whole or in part, nor passed to any third party.

cians [5]. The diagnosis of CVT depends on neuroimaging studies based on clinician's suspicion, especially in brain computed tomography (CT) and magnetic resonance (MR) imaging. Its pathophysiology is thought to be a combination of the anatomical structure of the cerebral venous system and systemic hypercoagulability due to infection, trauma, oral contraceptive, puerperium, and malignancy. The treatment strategy is based on anticoagulant, and the duration of the treatment varies with the presence of provocation factors.

12.3.1 Epidemiology of CVT

CVT is a rare disease. Given its vague presentation, diagnosis is still difficult, and this disease entity has been under-recognized so far. Despite sparsity of robust epidemiological evidence, the overall incidence of CVT is 1.32 per 100,000 person-year [11]. CVT accounts for 0.5%–1% of ischemic stroke cases. Especially, in young stroke patients, it occurs in seven cases per million, which is two times higher than that in the general population. Moreover, 5% of young stroke patients are diagnosed with CVT. In the International Study on Cerebral Vein and Dural Sinus Thrombosis study, approximately 45% of the patients were identified to have more than one cause of CVT, mainly as oral contraceptive use, thrombophilia, pregnancy, puerperium, and head and neck infections [12].

12.3.2 Pathophysiology of CVT

The Virchow triad is usually used to explain the pathophysiology of CVT (Fig. 12.4). Anatomically, superficial cerebral veins and sinuses lack tunica muscularis and valves, which allow bidirectional flow and therefore induce thrombus formation within the structure. In the

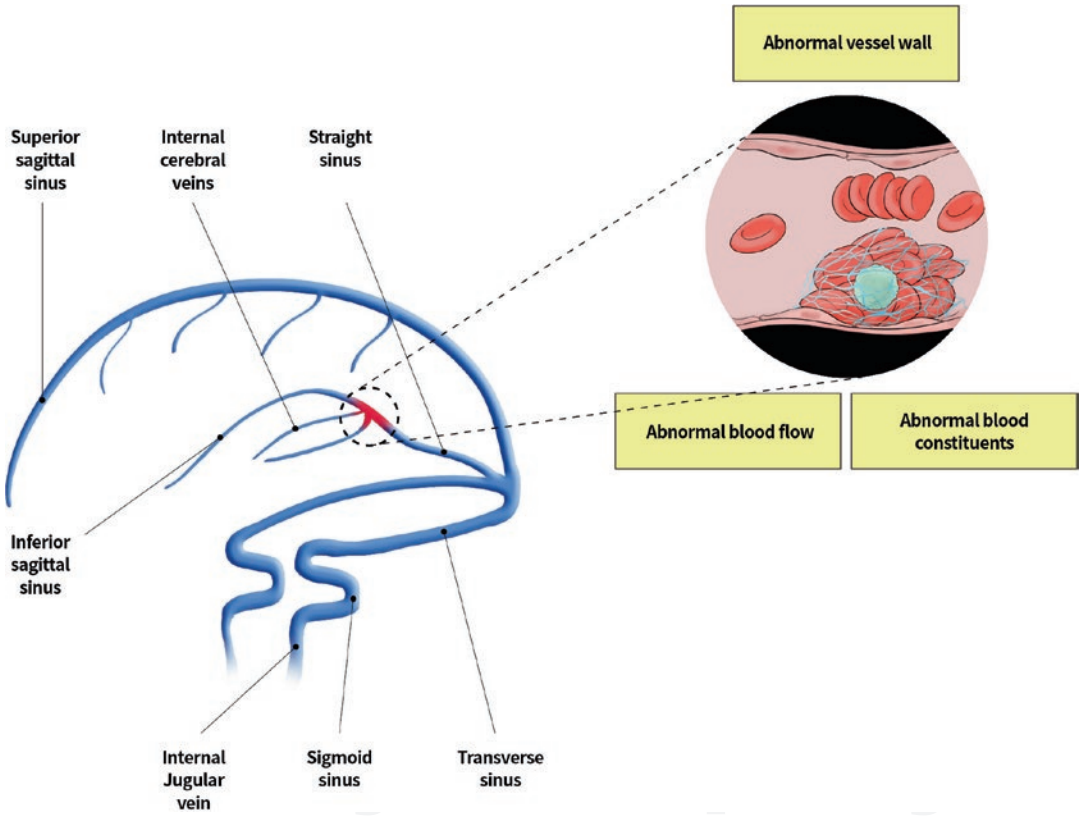

Fig. 12.4 Pathophysiology of cerebral venous thrombosis

This document is copyright of the original publisher. This document is strictly private, confidential and personal to its recipients and should not be copied, distributed or reproduced in whole or in part, nor passed to any third party.

superior sagittal sinus, scalp and cerebrospinal fluid (CSF) infections could evoke thrombosis due to anatomical adjacency. In case of a lateral sinus, the anatomical positioning near the mastoid increases their susceptibility to thrombosis induced by ear infection. Any blockage in the deep venous structure and poor venous outflow leads to the decreased CSF drainage, followed by increased the intracranial pressure. Another factor for CVT is systemic hypercoagulability. The hypercoagulable tendency is reported in patients not only with infection, but also cancer, nephrotic syndrome, inflammation, transient physiological states including dehydration and pregnancy, oral contraceptives, smoking, and head trauma [13]. Genetic causes are related to not only deficiency of prothrombin or protein C/S, but also AT3-deficient hyperhomocysteinemia.

12.3.3 Diagnosis of CVT

Experts' suspicion is a very important point in the diagnosis for CVT. Acute to subacute headache, young age, and bizarre neurology may be a clue to CVT. Clinical manifestations of CVT are less stereotyped than those of arterial stroke syndromes.

CVT is often presented as focal seizure or bilateral neurologic symptoms, frontal lobe dysfunction in the superior sagittal veins; headache, ear pain, tinnitus, uncommon aphasia or neglect in the transverse sinus; orbital pain, diplopia, ptosis, palsy of cranial nerve which pass through the cavernous sinus, mental status changes, and rapid neurological deterioration in the deep vein system. In severe cases, CVT of the deep vein system could result in coma. As above, the clinical presentation is dependent on the location of the thrombosis.

CVT diagnosis is made by suspicion through symptom and imaging evaluation. Pre-contrast CT, enhanced CT angiography, CT venography, brain MR imaging, MR angiography, and MR venography are mainly used to reveal infarction of atypical vascular territory, hemorrhage, or brain edema. In the CT protocol, radiologically important imaging findings that improve the visualization of thrombus are as follows: cord sign (thrombosed cortical and deep vein), dense triangle sign (visualization of the clot inside the sinus, in the posterior portion of the superior sagittal sinus), empty delta sign with contrast agent in the CT protocol, isointense on T1 imaging, hypointense on T2 imaging, and blooming effect of the gradient echo or susceptibility weighted imaging in the MR protocol.

In summary, if CVT is clinically suspected, brain imaging should be actively performed, considering the anatomic correlation with venous structure in the interpretation of symptoms.

12.3.4 Treatment of CVT

The first step in the treatment of CVT is the elimination of possible causes of thrombogenicity. The main purpose of CVT treatment is to remove thrombi and recanalization of the venous system. Clinicians may fear hemorrhagic complications of medications to treat CVT, especially in case of anticoagulation. However, anticoagulation facilitates recanalization and resolves deep venous thrombosis. Therefore, the use of anticoagulation is not a contraindication in the treatment of CVT. The recommended treatment is oral vitamin K antagonist (INR 2.0–3.0), unfractionated heparin, or LMWH. In addition, treatment dura-

Table 12.4 Recommended treatment durations of cerebral venous thrombosis

3 months	6–12 months	Indefinite
Provoked CVT	Idiopathic CVT	Recurrent CVT
Transient provocation factor – Infection – Trauma – Immobility – Medication	Mild thrombophilia – Heterozygous FVL – Heterozygous prothrombin	Severe thrombophilia – Antithrombin mutation – Protein C/S deficiency – Homozygous FVL mutation – Homozygous prothrombin mutation – Antiphospholipid antibody

CVT cerebral venous thrombosis, *FVL* factor V Leiden

This document is copyright of the original publisher. This document is strictly private, confidential and personal to its recipients and should not be copied, distributed or reproduced in whole or in part, nor passed to any third party.

tion of CVT depends on the presence of the trigger factor (Table 12.4).

Symptomatically, if a patient has a history of seizure due to CVT, antiepileptic drug should be used. Preventive prescription of an antiepileptic drug is not recommended. Decreased mental status due to increased intracranial pressure may be managed by mannitol, sedation, or endovascular treatment.

12.4 Other Hypercoagulability-Related Conditions

Hypercoagulability, the third component of Virchow's triad, may indicate systemic alterations in blood coagulability [14]. Hypercoagulability can be primary or secondary. Most primary hypercoagulable states are related to genetic background; deficiency of antithrombotic protein such as antithrombin, protein C/S, and increased prothrombotic protein such as factor V Leiden or prothrombin gene mutation. However, in this chapter, the authors will not elaborate on primary hypercoagulability because of its rarity. In this section, we focus on the cause of secondary hypercoagulability.

12.4.1 Myeloproliferative Disorder

Myeloproliferative disorders are a group of bone marrow stem cell disorders characterized by clonal expansion of abnormal hematopoietic cells [15]. It includes polycythemia vera (PV), essential thrombocythemia (ET), and myelofibrosis (MF). Venous and arterial thrombosis, including stroke, are major causes of morbidity and mortality in myeloproliferative disorders. The thrombosis induced by stem cell disorder can occur in large, small, or microvessels. Ischemic stroke occurs in 8% of patients with PV, 1.5% in patients with ET, and 3% in patients with MF [16]. ET is known to have the most favorable outcome. The proposed mechanism of stroke includes two aspects. First, the increase in blood cell counts correlates with the increased risk of stroke by hyperviscosity of blood and changed characteristics of blood cell, such as the cell membrane and procoagulant activation. Second, proteolytic activities, secretion of inflammatory cytokines, and expression of adhesion molecules were altered through Janus kinase 2 (JAK2), a gain-of-function mutation at the site of V617F. JAK2 mutation with erythrocytosis, leukocytosis, and thrombocytosis is a prognostic marker of stroke in myeloproliferative disease (Fig. 12.5). A clinician can evaluate the risk of stroke in patients with hematopoietic disease by using some tiered system, so we can decide on certain prophylactic agent and/or antithrombotic drugs. Aspirin, hydroxyurea, anagrelide, phlebotomy, and cytoreduction were recommended according to risk stratifications of myeloproliferative disease.

12.4.2 Pregnancy-Related Stroke

From the pregnancy period to the first postpartum period up to 8 weeks, the association with stroke increased up to fivefold. Pregnancy-related stroke occurred in 1 of 1500 pregnancies [17]. The pathophysiology of pregnancy-related hypercoagulability involves induced hypercoagulability due to increased procoagulant activity and changes in the vessels of the entire body [14]. Pregnancy induces elevation of the levels of coagulation factors V, VII, VIII, IX, X, and XII, fibrinogen, von Willebrand Factor, D-dimer, thrombin activatable fibrinolysis inhibitor (TAFI), and plasminogen activator inhibitor (PAI). It also induces a decrease in anticoagulant proteins, such as antithrombin, protein C, protein S, and tissue plasminogen activator [16]. These changes help minimize maternal blood loss during delivery. At the same time, however, these changes could predispose to stroke and placental vascular complications to the mother. These changes occur during the entire pregnancy period but are more pronounced in the third trimester until puerperium. Three weeks after delivery, altered blood coagulation and fibrinolysis generally returned to normal.

The treatment of pregnancy-related stroke was unfractionated heparin or LMWH instead of warfarin because of the teratogenic potential of the

This document is copyright of the original publisher. This document is strictly private, confidential and personal to its recipients and should not be copied, distributed or reproduced in whole or in part, nor passed to any third party.

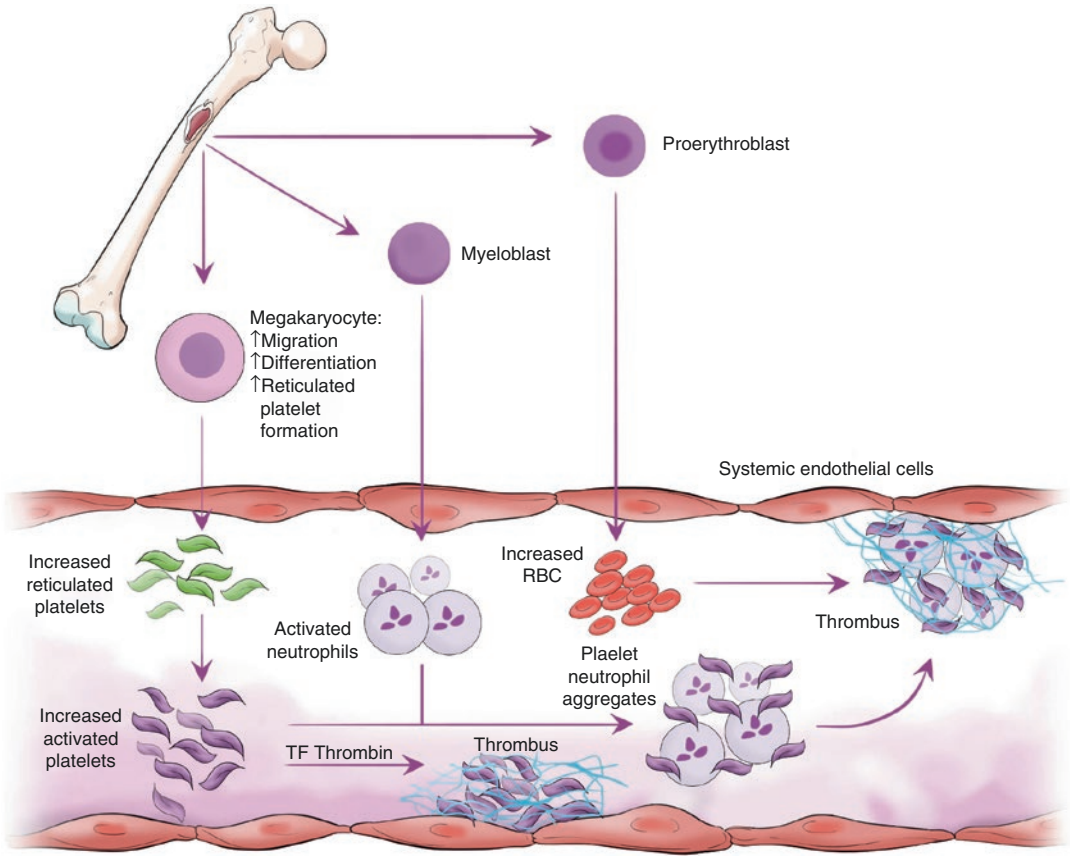

Fig. 12.5 Pathophysiology of myeloproliferative disease. Adapted with permission from Leukemia, Copyright Springer Nature [14]

latter. Low-dose aspirin was known to be safe, but clinicians should keep in mind early closure of patent ductus arteriosus in the fetus as a complication of aspirin therapy.

12.4.3 Oral Contraceptives and Hormonal Therapy

In women on conception by oral pill or assisted reproductive treatment, the risk of stroke is significantly high. The mechanisms of stroke by hormonal therapy are similar to those found in pregnancy, via the altered activity of blood coagulation and fibrinolysis. The risk of stroke is increased about two to sixfold with the use of oral contraceptives and hormone replacement therapy, despite the difference in the components of oral contraceptives [18]. The key player of the thrombogenicity of oral contraceptives is estrogen compounds. Estrogen has a direct effect on the vascular wall, either on the artery or venous system, mainly via the matrix metalloproteinase (MMP) pathway. MMP has a role in the cleavage of connective filaments, such as collagen and elastin in the vascular intima. It induces the metabolism of lipids and lipoprotein, increases the level of low-density lipoprotein and triglyceride, and decreases the level of high-density lipoprotein [16]. The main discordant point with pregnancy-related stroke is that protein C levels may increase, which may help identify a global hypercoagulable state. The level of protein C has been found to be higher in oral contraceptive users than in non-users. Progesterone-only oral contraceptives have generally no or little

This document is copyright of the original publisher. This document is strictly private, confidential and personal to its recipients and should not be copied, distributed or reproduced in whole or in part, nor passed to any third party.

effect on plasma lipoprotein levels, as wells as the risk of stroke [19]. The treatment of oral contraceptive-related stroke is to eliminate provocation factor as soon as possible and conversion to another therapy that has less effect on thrombogenicity.

References

1. Karen S, Savino S, Philip G, Katrien D, Soren J, Beverley JH, et al. Antiphospholipid syndrome. Nat Rev Dis Primers. 2018;4:17103. https://doi.org/10.1038/nrdp.2017.103.
2. Klara G, Gyula D. Antiphospholipid syndrome and thrombocytopenia. Thrombocytopenia. 2017; https://doi.org/10.5772/intechopen.72509.
3. Seung-Hoon L, editor. Stroke revisitied: diagnosis and treatment of ischemic stroke. Singapore: Springer; 2017.
4. Garcia D, Erkan D. Diagnosis and management of the antiphospholipid syndrome. N Engl J Med. 2018;378:2010–21.
5. Hannah C, Beverley JH, Maria E, Deepa RJ, Ian JM, RAPS trial investigators, et al. Rivaroxaban versus warfarin to treat patients with thrombotic antiphospholipid syndrome, with or without systemic lupus erythematosus (RAPS): a randomised, controlled, open-label, phase 2/3, non-inferiority trial. Lancet Haematol. 2016;3(9):e426–36.
6. Babak BN, Costantino L. Ischemic stroke in cancer patients: a review of an underappreciated pathology. Ann Neurol. 2018;83(5):873–83.
7. Efthimios D, Athiana MA, Sofia M, Vasileios S, Konstantinos T, Aristidis T, et al. Cancer-associated stroke: pathophysiology, detection and management (review). Int J Oncol. 2019;54(3):779–96.
8. Syed WY, Bhanu PV, Lakshmi SM, Sunil K. Radiation-induced cardiovascular disease: a clinical perspective. Front Cardiovasc Med. 2017;4:66. https://doi.org/10.3389/fcvm.2017.00066.
9. Nam KW, Kim CK, Kim TJ, An SJ, Oh KM, Yoon BW. Predictors of 30-day mortality and the risk of recurrent systemic thromboembolism in cancer patients suffering acute ischemic stroke. PLoS One. 2017;12(3):e0172793. https://doi.org/10.1371/journal.pone.0172793.
10. Vlasta VC. Microembolus detection by transcranial Doppler sonography: review of the literature. Stroke Res Treat. 2012;2012:382361. https://doi.org/10.1155/2012/382361.
11. Celestin D, Temgoua NM, Joel NT, Ronni T, Jean JB. Global epidemiology and patterns of cerebral venous thrombosis: a systematic review and meta-analysis protocol. BMJ Open. 2017;8:e019939. https://doi.org/10.1136/bmjopen-2017-019939.
12. Ferro JM, Canhao P, Stam J, Bousser MG, Barinagarrementeria F, Investigators ISCVT. Prognosis of cerebral vein and dural sinus thrombosis: results of the International Study on Cerebral Vein and Dural Sinus Thrombosis (ISCVT). Stroke. 2004;35(3):664–70.
13. Christopher AS, John WC. Cerebral venous thrombosis: a clinical overview. Ischemic Stroke Brain. 2018; https://doi.org/10.5772/intechopen.79049.
14. Andrew IS. Hypercoagulable state. In: James TW, JJW H, Jay NC, David RH, editors. Cardiovascular medicine. 3rd ed. Philadelphia: Churchill Livingstone; 2000. p. 2423–38.
15. Falchi L, Kantarjian HM, Verstovsek S. Assessing the thrombotic risk of patients with essential thrombocythemia in the genomic era. Leukemia. 2017;31:1845–54.
16. Ong E, Barraco F, Nighoghossian N, Praire A, Desestret V, Biotti D. Cerebrovascular events as presenting manifestations of myeloproliferative neoplasm. Rev Neurol. 2016;172(11):703–8.
17. Emanuele P, Paolo B, Serena M, Ida M. Risk factors for venous and arterial thrombosis. Blood Transfus. 2011;9:120–38.
18. Patricia HD. Use of oral contraceptives and postmenopausal hormone replacement: evidence on risk of stroke. Curr Treat Options Neurol. 2008;10(6):468–74.
19. Caitlin C, Matthew B, Sophia S. Oral contraceptives and ischemic stroke risk. Stroke. 2018;49:e157–9.

This document is copyright of the original publisher. This document is strictly private, confidential and personal to its recipients and should not be copied, distributed or reproduced in whole or in part, nor passed to any third party.